Amygdala
Brain_supratentorial
Brainstem_interior
Brainstem_surface
CaudateNucleus
Cerebellum
Cerebellum_A
Cerebellum_P
Chiasm
Cochlea
Cornea
CorpusCallosum
Fornix
Fovea_rc
Glnd_lacrimal
Glnd_Pineal
Hippocampus
UPDATE
EEKERS © 2021
EPTH ATLAS
CONTOURING
2021-02-28
Hippocampus_A
Hippocampus_P
Hypothalamus
Lens
Macula_rc
MedullaOblongata
Midbrain
Optic_nerve
Optic_tract
Orbitofrontal
Pituitary
Pons
Retina
Skin
Spinal cord
Thalamus
Ventricles
VSCC

Amygdala
Brain_supratentorial
Brainstem_interior
Brainstem_surface
CaudateNucleus
Cerebellum
Cerebellum_A
Cerebellum_P
Chiasm
Cochlea
Cornea
CorpusCallosum
Fornix
Fovea_rc
Glnd_lacrimal
Glnd_Pineal
Hippocampus
UPDATE
EEKERS © 2021
EPTH ATLAS
CONTOURING
2021-02-28
Hippocampus_A
Hippocampus_P
Hypothalamus
Lens
Macula_rc
MedullaOblongata
Midbrain
Optic_nerve
Optic_tract
Orbitofrontal
Pituitary
Pons
Retina
Skin
Spinal cord
Thalamus
Ventricles
VSCC

Amygdala
Brain_supratentorial
Brainstem_interior
Brainstem_surface
CaudateNucleus
Cerebellum
Cerebellum_A
Cerebellum_P
Chiasm
Cochlea
Cornea
CorpusCallosum
Fornix
Fovea_rc
Glnd_lacrimal
Glnd_Pineal
Hippocampus
UPDATE
EEKERS © 2021
EPTH ATLAS
CONTOURING
2021-02-28
Hippocampus_A
Hippocampus_P
Hypothalamus
Lens
Macula_rc
MedullaOblongata
Midbrain
Optic_nerve
Optic_tract
Orbitofrontal
Pituitary
Pons
Retina
Skin
Spinal cord
Thalamus
Ventricles
VSCC

Amygdala
Brain_supratentorial
Brainstem_interior
Brainstem_surface
CaudateNucleus
Cerebellum
Cerebellum_A
Cerebellum_P
Chiasm
Cochlea
Cornea
CorpusCallosum
Fornix
Fovea_rc
Glnd_lacrimal
Glnd_Pineal
Hippocampus
UPDATE
EEKERS © 2021
EPTH ATLAS
CONTOURING
2021-02-18
Hippocampus_A
Hippocampus_P
Hypothalamus
Lens
Macula_rc
MedullaOblongata
Midbrain
Optic_nerve
Optic_tract
Orbitofrontal
Pituitary
Pons
Retina
Skin
Spinal cord
Thalamus
Ventricles
VSCC

Amygdala
Brain_supratentorial
Brainstem_interior
Brainstem_surface
CaudateNucleus
Cerebellum
Cerebellum_A
Cerebellum_P
Chiasm
Cochlea
Cornea
CorpusCallosum
Fornix
Fovea_rc
Glnd_lacrimal
Glnd_Pineal
Hippocampus
UPDATE
EEKERS © 2021
EPTH ATLAS
CONTOURING
2021-02-18
Hippocampus_A
Hippocampus_P
Hypothalamus
Lens
Macula_rc
MedullaOblongata
Midbrain
Optic_nerve
Optic_tract
Orbitofrontal
Pituitary
Pons
Retina
Skin
Spinal cord
Thalamus
Ventricles
VSCC

Amygdala
Brain_supratentorial
Brainstem_interior
Brainstem_surface
CaudateNucleus
Cerebellum
Cerebellum_A
Cerebellum_P
Chiasm
Cochlea
Cornea
CorpusCallosum
Fornix
Fovea_rc
Glnd_lacrimal
Glnd_Pineal
Hippocampus
UPDATE
EEKERS © 2021
EPTH ATLAS
CONTOURING
2021-02-28
Hippocampus_A
Hippocampus_P
Hypothalamus
Lens
Macula_rc
MedullaOblongata
Midbrain
Optic_nerve
Optic_tract
Orbitofrontal
Pituitary
Pons
Retina
Skin
Spinal cord
Thalamus
Ventricles
VSCC

Amygdala
Brain_supratentorial
Brainstem_interior
Brainstem_surface
CaudateNucleus
Cerebellum
Cerebellum_A
Cerebellum_P
Chiasm
Cochlea
Cornea
CorpusCallosum
Fornix
Fovea_rc
Glnd_lacrimal
Glnd_Pineal
Hippocampus
UPDATE
EEKERS © 2021
EPTH ATLAS
CONTOURING
2021-02-28
Hippocampus_A
Hippocampus_P
Hypothalamus
Lens
Macula_rc
MedullaOblongata
Midbrain
Optic_nerve
Optic_tract
Orbitofrontal
Pituitary
Pons
Retina
Skin
Spinal cord
Thalamus
Ventricles
VSCC

Amygdala
Brain_supratentorial
Brainstem_interior
Brainstem_surface
CaudateNucleus
Cerebellum
Cerebellum_A
Cerebellum_P
Chiasm
Cochlea
Cornea
CorpusCallosum
Fornix
Fovea_rc
Glnd_lacrimal
Glnd_Pineal
Hippocampus
UPDATE
EEKERS © 2021
EPTH ATLAS
CONTOURING
2021-02-18
Hippocampus_A
Hippocampus_P
Hypothalamus
Lens
Macula_rc
MedullaOblongata
Midbrain
Optic_nerve
Optic_tract
Orbitofrontal
Pituitary
Pons
Retina
Skin
Spinal cord
Thalamus
Ventricles
VSCC

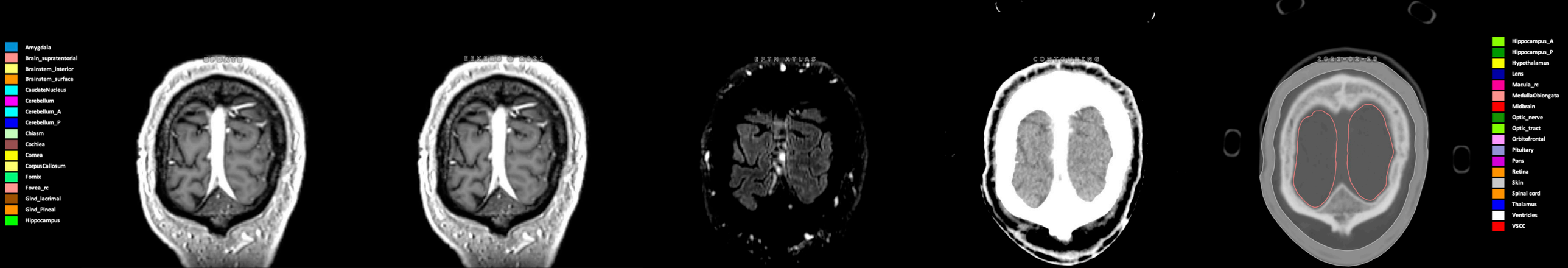
Amygdala
Brain_supratentorial
Brainstem_interior
Brainstem_surface
CaudateNucleus
Cerebellum
Cerebellum_A
Cerebellum_P
Chiasm
Cochlea
Cornea
CorpusCallosum
Fornix
Fovea_rc
Glnd_lacrimal
Glnd_Pineal
Hippocampus
UCDAVIS
EKKENS © 2021
EPTH ATLAS
CONTOURING
2021-04-28
Hippocampus_A
Hippocampus_P
Hypothalamus
Lens
Macula_rc
MedullaOblongata
Midbrain
Optic_nerve
Optic_tract
Orbitofrontal
Pituitary
Pons
Retina
Skin
Spinal cord
Thalamus
Ventricles
VSCC

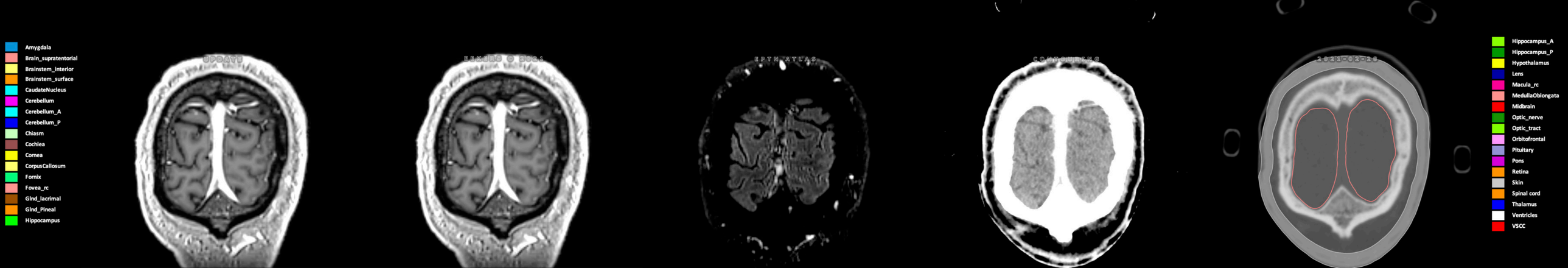
Amygdala
Brain_supratentorial
Brainstem_interior
Brainstem_surface
CaudateNucleus
Cerebellum
Cerebellum_A
Cerebellum_P
Chiasm
Cochlea
Cornea
CorpusCallosum
Fornix
Fovea_rc
Glnd_lacrimal
Glnd_Pineal
Hippocampus
Hippocampus_A
Hippocampus_P
Hypothalamus
Lens
Macula_rc
MedullaOblongata
Midbrain
Optic_nerve
Optic_tract
Orbitofrontal
Pituitary
Pons
Retina
Skin
Spinal cord
Thalamus
Ventricles
VSCC

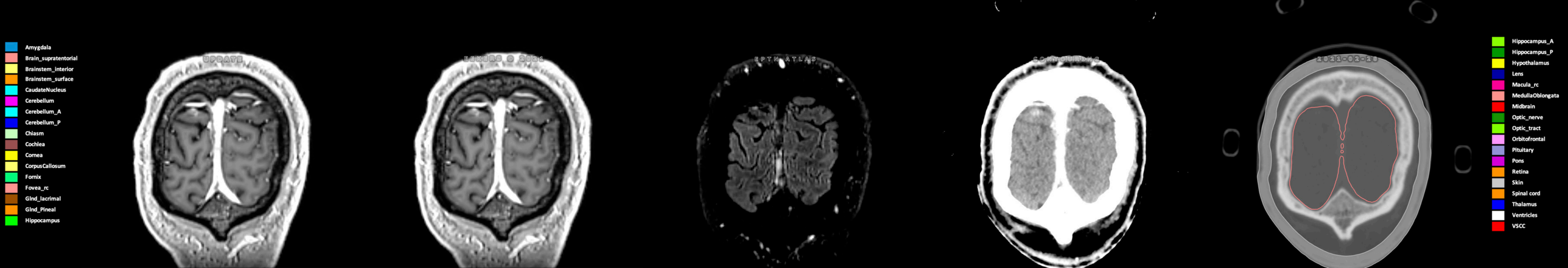
Amygdala
Brain_supratentorial
Brainstem_interior
Brainstem_surface
CaudateNucleus
Cerebellum
Cerebellum_A
Cerebellum_P
Chiasm
Cochlea
Cornea
CorpusCallosum
Fornix
Fovea_rc
Glnd_lacrimal
Glnd_Pineal
Hippocampus
Hippocampus_A
Hippocampus_P
Hypothalamus
Lens
Macula_rc
MedullaOblongata
Midbrain
Optic_nerve
Optic_tract
Orbitofrontal
Pituitary
Pons
Retina
Skin
Spinal cord
Thalamus
Ventricles
VSCC

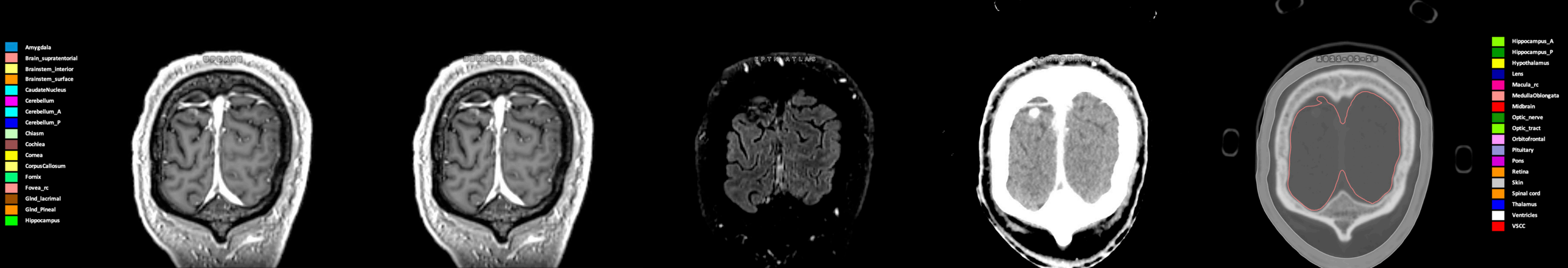
Amygdala
Brain_supratentorial
Brainstem_interior
Brainstem_surface
CaudateNucleus
Cerebellum
Cerebellum_A
Cerebellum_P
Chiasm
Cochlea
Cornea
CorpusCallosum
Fornix
Fovea_rc
Glnd_lacrimal
Glnd_Pineal
Hippocampus
Hippocampus_A
Hippocampus_P
Hypothalamus
Lens
Macula_rc
MedullaOblongata
Midbrain
Optic_nerve
Optic_tract
Orbitofrontal
Pituitary
Pons
Retina
Skin
Spinal cord
Thalamus
Ventricles
VSCC

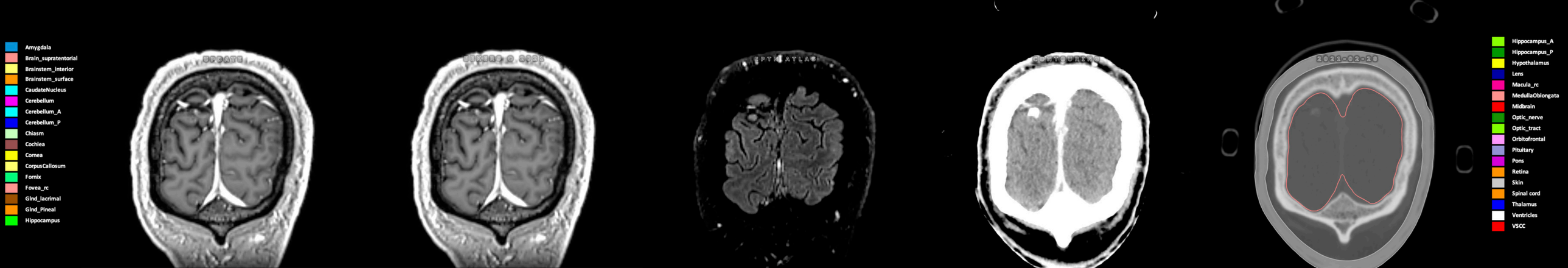
Amygdala
Brain_supratentorial
Brainstem_interior
Brainstem_surface
CaudateNucleus
Cerebellum
Cerebellum_A
Cerebellum_P
Chiasm
Cochlea
Cornea
CorpusCallosum
Fornix
Fovea_rc
Gland_lacrimal
Gland_Pineal
Hippocampus
Hippocampus_A
Hippocampus_P
Hypothalamus
Lens
Macula_rc
MedullaOblongata
Midbrain
Optic_nerve
Optic_tract
Orbitofrontal
Pituitary
Pons
Retina
Skin
Spinal cord
Thalamus
Ventricles
VSCC

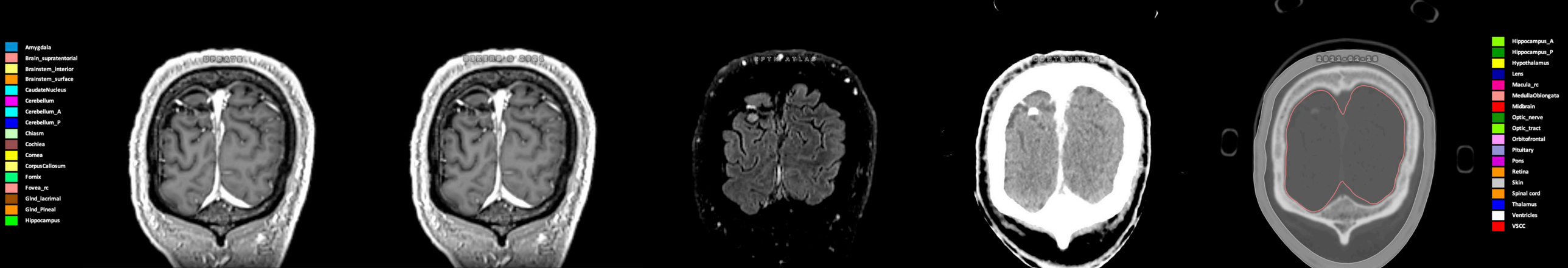
Amygdala
Brain_supratentorial
Brainstem_interior
Brainstem_surface
CaudateNucleus
Cerebellum
Cerebellum_A
Cerebellum_P
Chiasm
Cochlea
Cornea
CorpusCallosum
Fornix
Fovea_rc
Gland_lacrimal
Gland_Pineal
Hippocampus
Hippocampus_A
Hippocampus_P
Hypothalamus
Lens
Macula_rc
MedullaOblongata
Midbrain
Optic_nerve
Optic_tract
Orbitofrontal
Pituitary
Pons
Retina
Skin
Spinal cord
Thalamus
Ventricles
VSCC

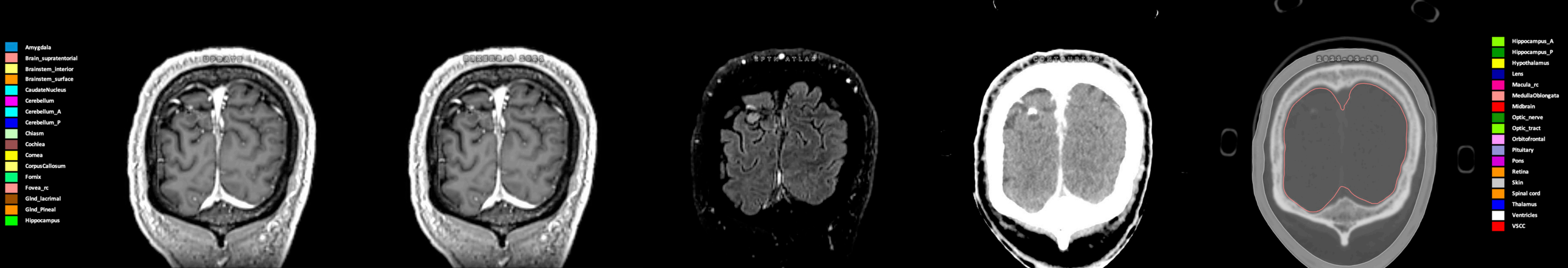
Amygdala
Brain_supratentorial
Brainstem_interior
Brainstem_surface
CaudateNucleus
Cerebellum
Cerebellum_A
Cerebellum_P
Chiasm
Cochlea
Cornea
CorpusCallosum
Fornix
Fovea_rc
Glnd_lacrimal
Glnd_Pineal
Hippocampus
UPDATE
EPTN ATLAS
CONTOURS
2021-02-28
Hippocampus_A
Hippocampus_P
Hypothalamus
Lens
Macula_rc
MedullaOblongata
Midbrain
Optic_nerve
Optic_tract
Orbitofrontal
Pituitary
Pons
Retina
Skin
Spinal cord
Thalamus
Ventricles
VSCC

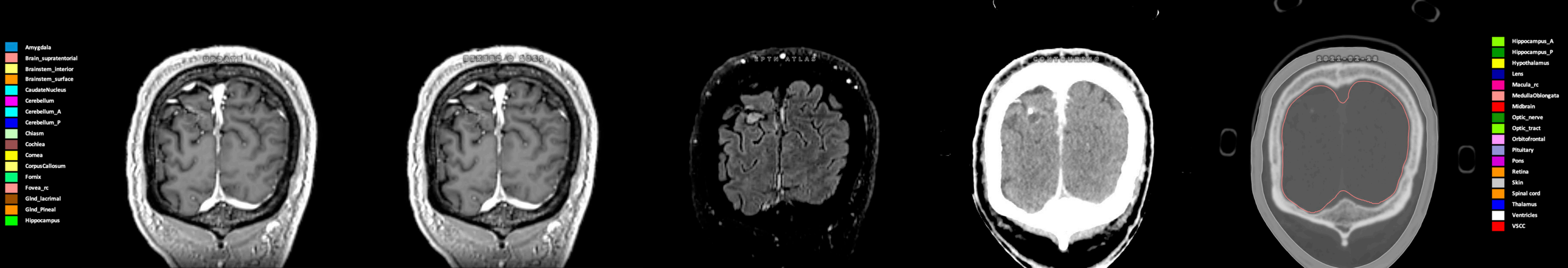
Amygdala
Brain_supratentorial
Brainstem_interior
Brainstem_surface
CaudateNucleus
Cerebellum
Cerebellum_A
Cerebellum_P
Chiasm
Cochlea
Cornea
CorpusCallosum
Fornix
Fovea_rc
Glnd_lacrimal
Glnd_Pineal
Hippocampus
UPDATE
EPTN ATLAS
CONTOURED
2021-02-28
Hippocampus_A
Hippocampus_P
Hypothalamus
Lens
Macula_rc
MedullaOblongata
Midbrain
Optic_nerve
Optic_tract
Orbitofrontal
Pituitary
Pons
Retina
Skin
Spinal cord
Thalamus
Ventricles
VSCC

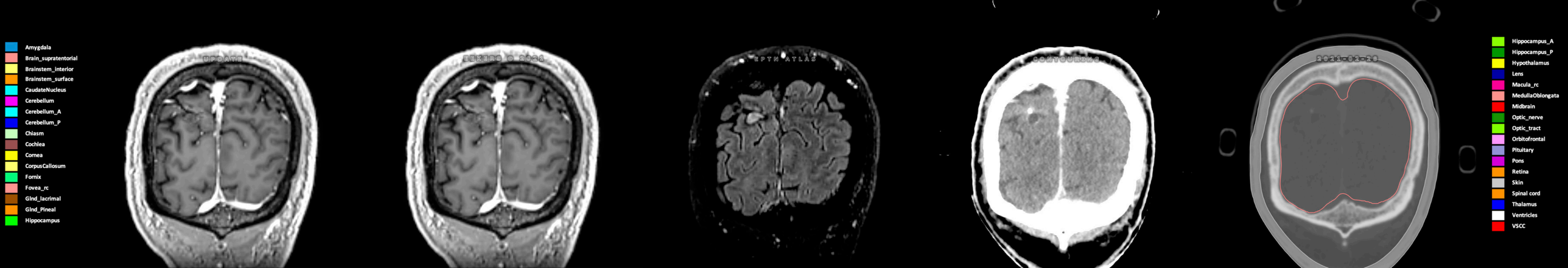
Amygdala
Brain_supratentorial
Brainstem_interior
Brainstem_surface
CaudateNucleus
Cerebellum
Cerebellum_A
Cerebellum_P
Chiasm
Cochlea
Cornea
CorpusCallosum
Fornix
Fovea_rc
Glnd_lacrimal
Glnd_Pineal
Hippocampus
Hippocampus_A
Hippocampus_P
Hypothalamus
Lens
Macula_rc
MedullaOblongata
Midbrain
Optic_nerve
Optic_tract
Orbitofrontal
Pituitary
Pons
Retina
Skin
Spinal cord
Thalamus
Ventricles
VSCC

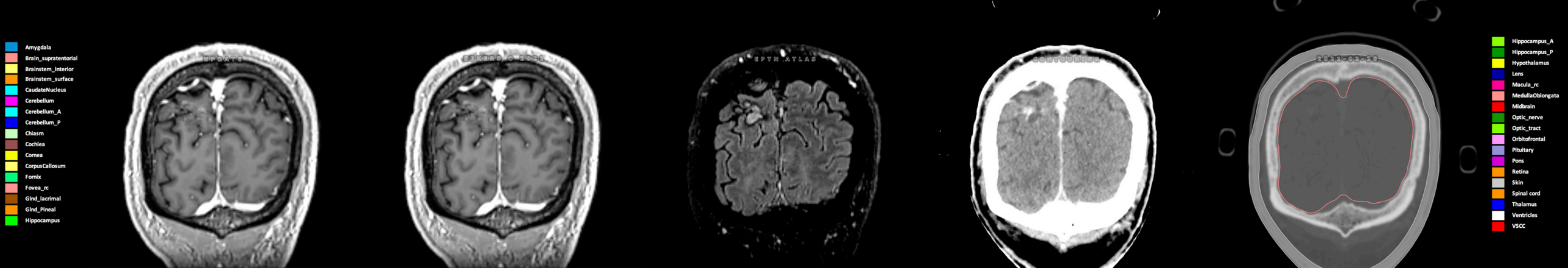
Amygdala
Brain_supratentorial
Brainstem_interior
Brainstem_surface
CaudateNucleus
Cerebellum
Cerebellum_A
Cerebellum_P
Chiasm
Cochlea
Cornea
CorpusCallosum
Fornix
Fovea_rc
Glnd_lacrimal
Glnd_Pineal
Hippocampus
UPDATE
EPTN ATLAS
CONTOURING
2021-02-13
Hippocampus_A
Hippocampus_P
Hypothalamus
Lens
Macula_rc
MedullaOblongata
Midbrain
Optic_nerve
Optic_tract
Orbitofrontal
Pituitary
Pons
Retina
Skin
Spinal cord
Thalamus
Ventricles
VSCC

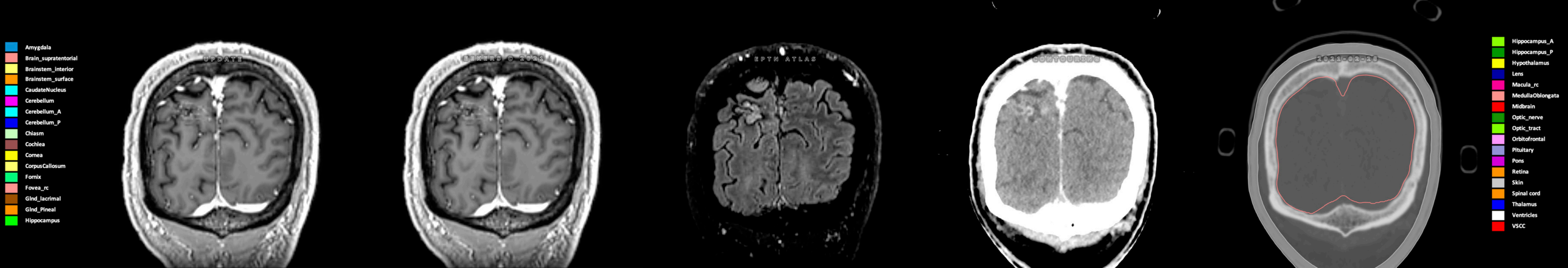
Amygdala
Brain_supratentorial
Brainstem_interior
Brainstem_surface
CaudateNucleus
Cerebellum
Cerebellum_A
Cerebellum_P
Chiasm
Cochlea
Cornea
CorpusCallosum
Fornix
Fovea_rc
Glnd_lacrimal
Glnd_Pineal
Hippocampus
UPDATE
EPTH ATLAS
CONTOURED
2021-02-26
Hippocampus_A
Hippocampus_P
Hypothalamus
Lens
Macula_rc
MedullaOblongata
Midbrain
Optic_nerve
Optic_tract
Orbitofrontal
Pituitary
Pons
Retina
Skin
Spinal cord
Thalamus
Ventricles
VSCC

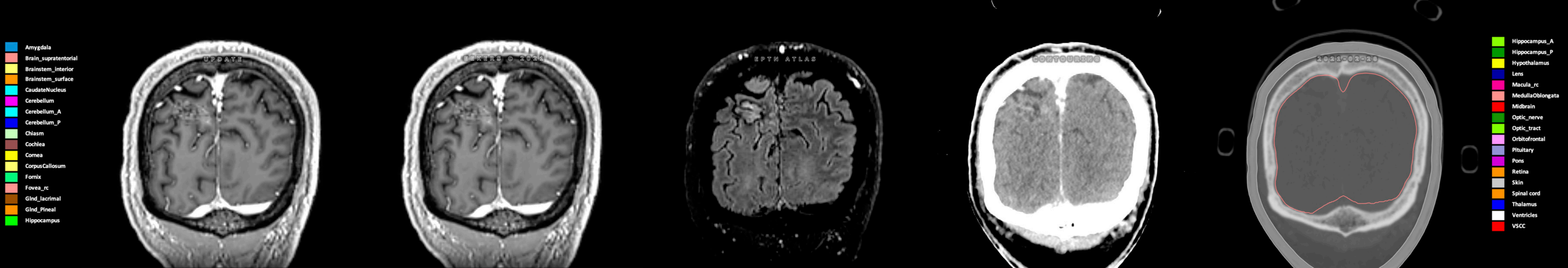
Amygdala
Brain_supratentorial
Brainstem_interior
Brainstem_surface
CaudateNucleus
Cerebellum
Cerebellum_A
Cerebellum_P
Chiasm
Cochlea
Cornea
CorpusCallosum
Fornix
Fovea_rc
Glnd_lacrimal
Glnd_Pineal
Hippocampus
UPDATE
EPTH ATLAS
CONTOURING
2021-02-26
Hippocampus_A
Hippocampus_P
Hypothalamus
Lens
Macula_rc
MedullaOblongata
Midbrain
Optic_nerve
Optic_tract
Orbitofrontal
Pituitary
Pons
Retina
Skin
Spinal cord
Thalamus
Ventricles
VSCC

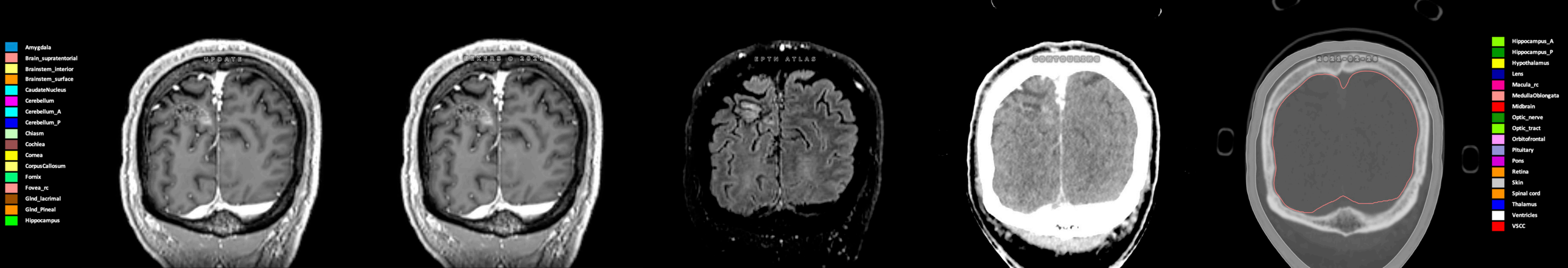
Amygdala
Brain_supratentorial
Brainstem_interior
Brainstem_surface
CaudateNucleus
Cerebellum
Cerebellum_A
Cerebellum_P
Chiasm
Cochlea
Cornea
CorpusCallosum
Fornix
Fovea_rc
Glnd_lacrimal
Glnd_Pineal
Hippocampus
UPDATE
EPTH ATLAS
CONTOURING
2021-08-18
Hippocampus_A
Hippocampus_P
Hypothalamus
Lens
Macula_rc
MedullaOblongata
Midbrain
Optic_nerve
Optic_tract
Orbitofrontal
Pituitary
Pons
Retina
Skin
Spinal cord
Thalamus
Ventricles
VSCC

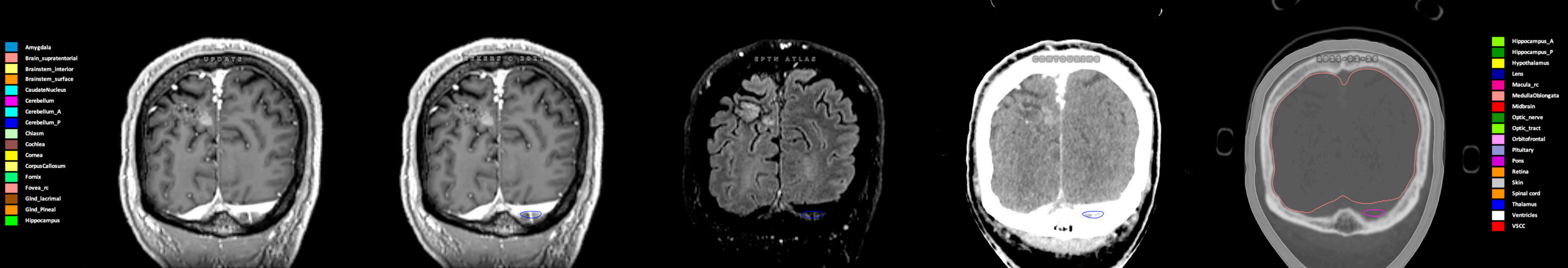
Amygdala
Brain_supratentorial
Brainstem_interior
Brainstem_surface
CaudateNucleus
Cerebellum
Cerebellum_A
Cerebellum_P
Chiasm
Cochlea
Cornea
CorpusCallosum
Fornix
Fovea_rc
Gland_lacrimal
Gland_Pineal
Hippocampus
UPDATE
EPTH ATLAS
CONTOURING
2021-02-26
Hippocampus_A
Hippocampus_P
Hypothalamus
Lens
Macula_rc
MedullaOblongata
Midbrain
Optic_nerve
Optic_tract
Orbitofrontal
Pituitary
Pons
Retina
Skin
Spinal cord
Thalamus
Ventricles
VSCC

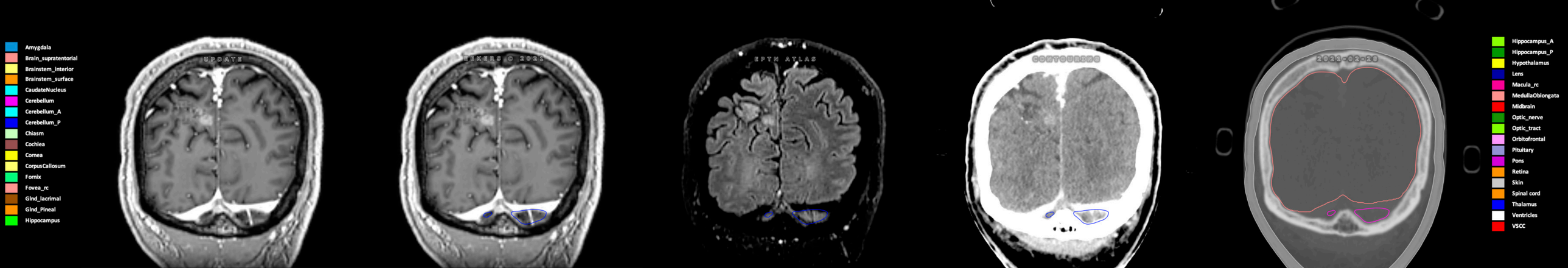
Amygdala
Brain_supratentorial
Brainstem_interior
Brainstem_surface
CaudateNucleus
Cerebellum
Cerebellum_A
Cerebellum_P
Chiasm
Cochlea
Cornea
CorpusCallosum
Fornix
Fovea_rc
Gland_lacrimal
Gland_Pineal
Hippocampus
UPDATE
EPTN ATLAS
CONTOURING
2021-02-26
Hippocampus_A
Hippocampus_P
Hypothalamus
Lens
Macula_rc
MedullaOblongata
Midbrain
Optic_nerve
Optic_tract
Orbitofrontal
Pituitary
Pons
Retina
Skin
Spinal cord
Thalamus
Ventricles
VSCC

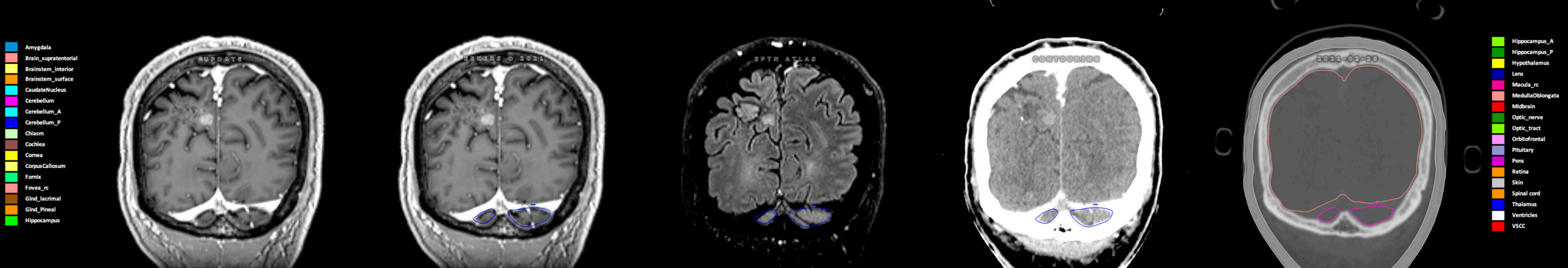
Amygdala
Brain_supratentorial
Brainstem_interior
Brainstem_surface
CaudateNucleus
Cerebellum
Cerebellum_A
Cerebellum_P
Chiasm
Cochlea
Cornea
CorpusCallosum
Fornix
Fovea_rc
Glnd_lacrimal
Glnd_Pineal
Hippocampus
UPDATE
EPTH ATLAS
CONTOURING
2021-02-26
Hippocampus_A
Hippocampus_P
Hypothalamus
Lens
Macula_rc
MedullaOblongata
Midbrain
Optic_nerve
Optic_tract
Orbitofrontal
Pituitary
Pons
Retina
Skin
Spinal cord
Thalamus
Ventricles
VSCC

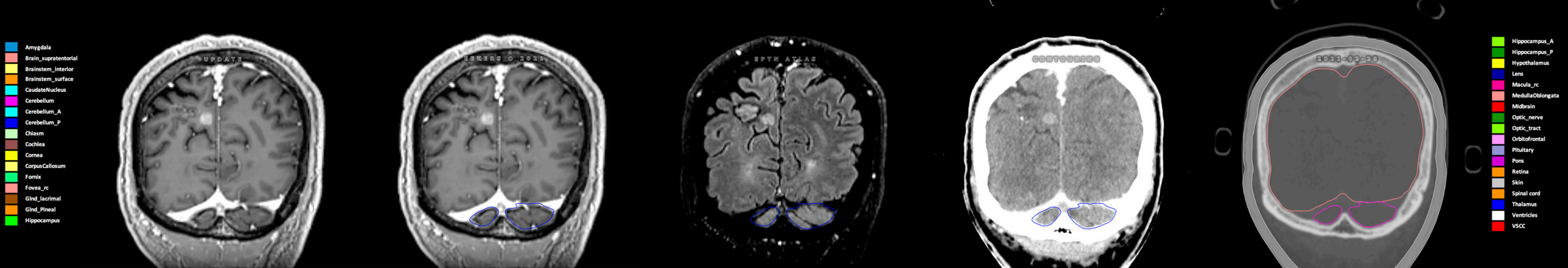
Amygdala
Brain_supratentorial
Brainstem_interior
Brainstem_surface
CaudateNucleus
Cerebellum
Cerebellum_A
Cerebellum_P
Chiasm
Cochlea
Cornea
CorpusCallosum
Fornix
Fovea_rc
Glnd_lacrimal
Glnd_Pineal
Hippocampus
UPDATE
EPTN ATLAS
CONTOURING
2021-02-26
Hippocampus_A
Hippocampus_P
Hypothalamus
Lens
Macula_rc
MedullaOblongata
Midbrain
Optic_nerve
Optic_tract
Orbitofrontal
Pituitary
Pons
Retina
Skin
Spinal cord
Thalamus
Ventricles
VSCC

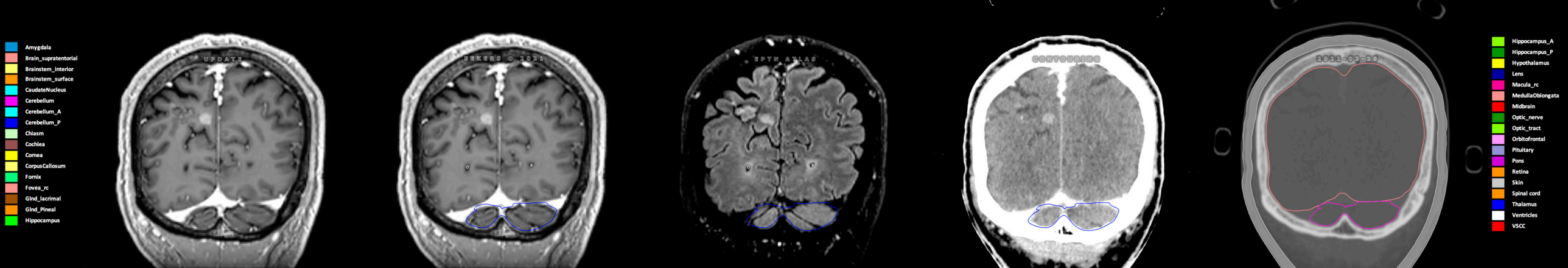
Amygdala
Brain_supratentorial
Brainstem_interior
Brainstem_surface
CaudateNucleus
Cerebellum
Cerebellum_A
Cerebellum_P
Chiasm
Cochlea
Cornea
CorpusCallosum
Fornix
Fovea_rc
Glnd_lacrimal
Glnd_Pineal
Hippocampus
UPDATE
EEKERS © 2021
EPTH ATLAS
CONTOURING
2021-02-26
Hippocampus_A
Hippocampus_P
Hypothalamus
Lens
Macula_rc
MedullaOblongata
Midbrain
Optic_nerve
Optic_tract
Orbitofrontal
Pituitary
Pons
Retina
Skin
Spinal cord
Thalamus
Ventricles
VSCC

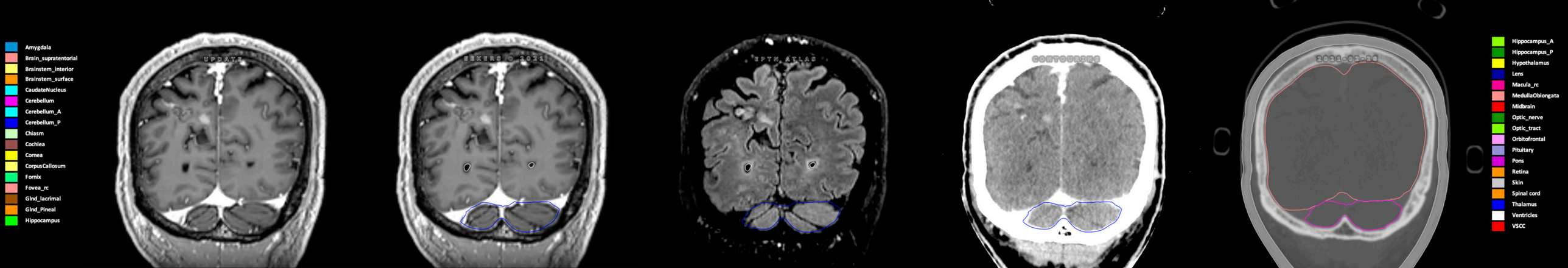
Amygdala
Brain_supratentorial
Brainstem_interior
Brainstem_surface
CaudateNucleus
Cerebellum
Cerebellum_A
Cerebellum_P
Chiasm
Cochlea
Cornea
CorpusCallosum
Fornix
Fovea_rc
Gland_lacrimal
Gland_Pineal
Hippocampus
UPDATE
EEKERS © 2021
EPTH ATLAS
CONTOURING
2021-02-26
Hippocampus_A
Hippocampus_P
Hypothalamus
Lens
Macula_rc
MedullaOblongata
Midbrain
Optic_nerve
Optic_tract
Orbitofrontal
Pituitary
Pons
Retina
Skin
Spinal cord
Thalamus
Ventricles
VSCC

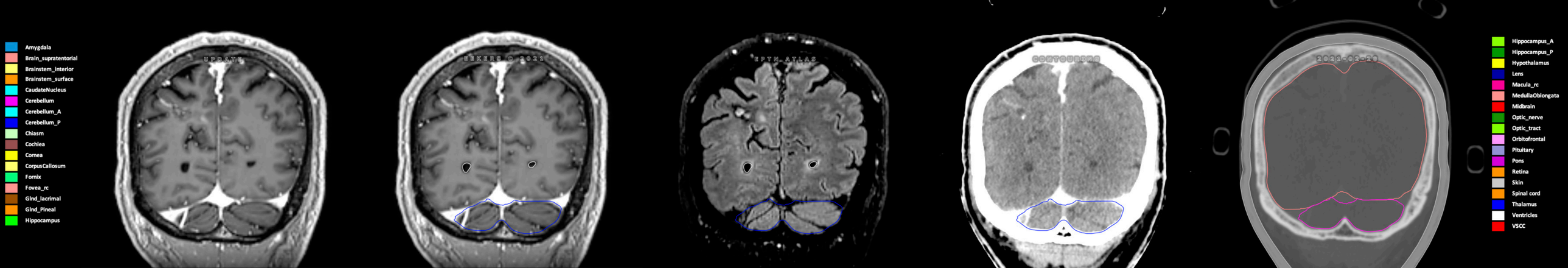
Amygdala
Brain_supratentorial
Brainstem_interior
Brainstem_surface
CaudateNucleus
Cerebellum
Cerebellum_A
Cerebellum_P
Chiasm
Cochlea
Cornea
CorpusCallosum
Fornix
Fovea_rc
Gland_lacrimal
Gland_Pineal
Hippocampus
UPDATE
EKERS © 2021
EPTH_ATLAS
CONTOURING
2021-02-23
Hippocampus_A
Hippocampus_P
Hypothalamus
Lens
Macula_rc
MedullaOblongata
Midbrain
Optic_nerve
Optic_tract
Orbitofrontal
Pituitary
Pons
Retina
Skin
Spinal cord
Thalamus
Ventricles
VSCC

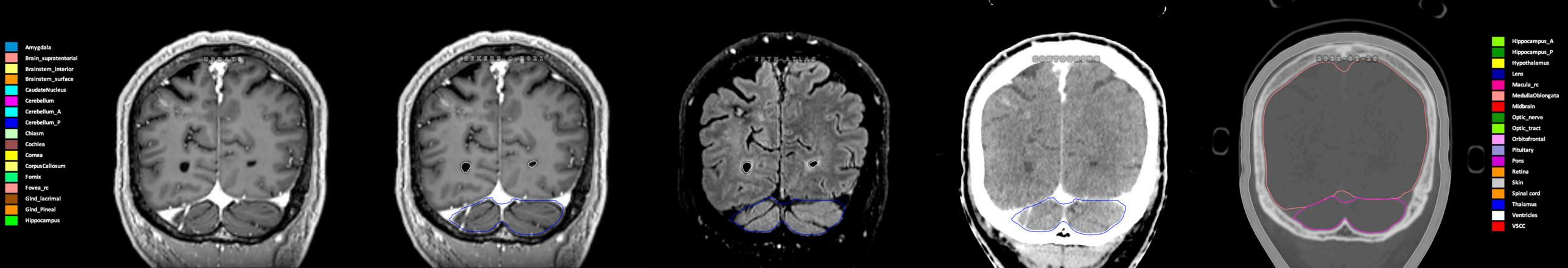
Amygdala
Brain_supratentorial
Brainstem_interior
Brainstem_surface
CaudateNucleus
Cerebellum
Cerebellum_A
Cerebellum_P
Chiasm
Cochlea
Cornea
CorpusCallosum
Fornix
Fovea_rc
Glnd_lacrimal
Glnd_Pineal
Hippocampus
UPDATE
EEKERS © 2021
EDYS-ATLAS
CONTOURING
2021-02-28
Hippocampus_A
Hippocampus_P
Hypothalamus
Lens
Macula_rc
MedullaOblongata
Midbrain
Optic_nerve
Optic_tract
Orbitofrontal
Pituitary
Pons
Retina
Skin
Spinal cord
Thalamus
Ventricles
VSCC

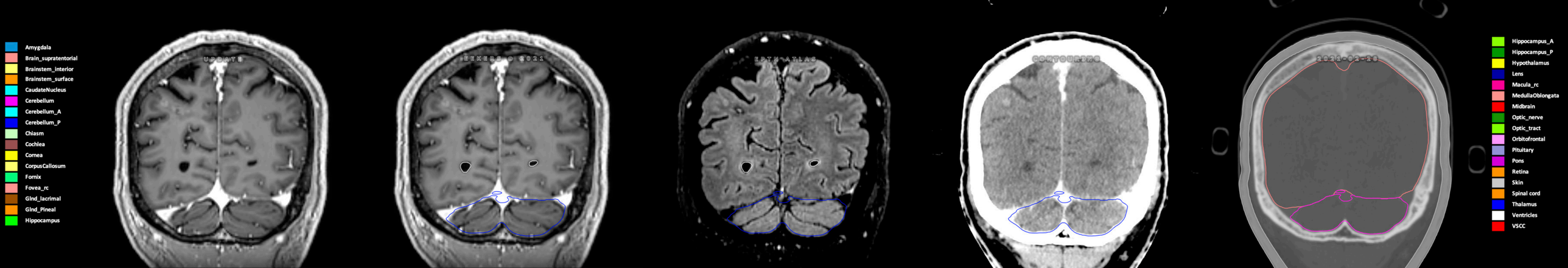
Amygdala
Brain_supratentorial
Brainstem_interior
Brainstem_surface
CaudateNucleus
Cerebellum
Cerebellum_A
Cerebellum_P
Chiasm
Cochlea
Cornea
CorpusCallosum
Fornix
Fovea_rc
Gland_lacrimal
Gland_Pineal
Hippocampus
UPDATE
HEINEN © 2021
EDTS-ATLAS
CONTOURING
2021-02-25
Hippocampus_A
Hippocampus_P
Hypothalamus
Lens
Macula_rc
MedullaOblongata
Midbrain
Optic_nerve
Optic_tract
Orbitofrontal
Pituitary
Pons
Retina
Skin
Spinal cord
Thalamus
Ventricles
VSCC

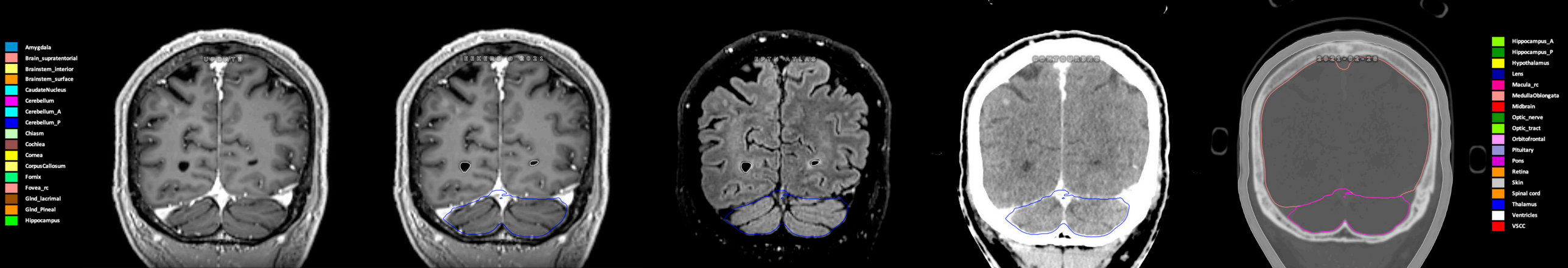
Amygdala
Brain_supratentorial
Brainstem_interior
Brainstem_surface
CaudateNucleus
Cerebellum
Cerebellum_A
Cerebellum_P
Chiasm
Cochlea
Cornea
CorpusCallosum
Fornix
Fovea_rc
Gland_lacrimal
Gland_Pineal
Hippocampus
UPDATE
EEKERS © 2021
EPTS ATLAS
CONTOURERS
2021-02-25
Hippocampus_A
Hippocampus_P
Hypothalamus
Lens
Macula_rc
MedullaOblongata
Midbrain
Optic_nerve
Optic_tract
Orbitofrontal
Pituitary
Pons
Retina
Skin
Spinal cord
Thalamus
Ventricles
VSCC

- 🟦 Amygdala
- 🟥 Brain_supratentorial
- 🟨 Brainstem_interior
- 🟧 Brainstem_surface
- 🟦 CaudateNucleus
- 🟪 Cerebellum
- 🟦 Cerebellum_A
- 🟦 Cerebellum_P
- 🟩 Chiasm
- 🟫 Cochlea
- 🟨 Cornea
- 🟨 CorpusCallosum
- 🟩 Fornix
- 🟥 Fovea_rc
- 🟫 Glnd_lacrimal
- 🟧 Glnd_Pineal
- 🟩 Hippocampus

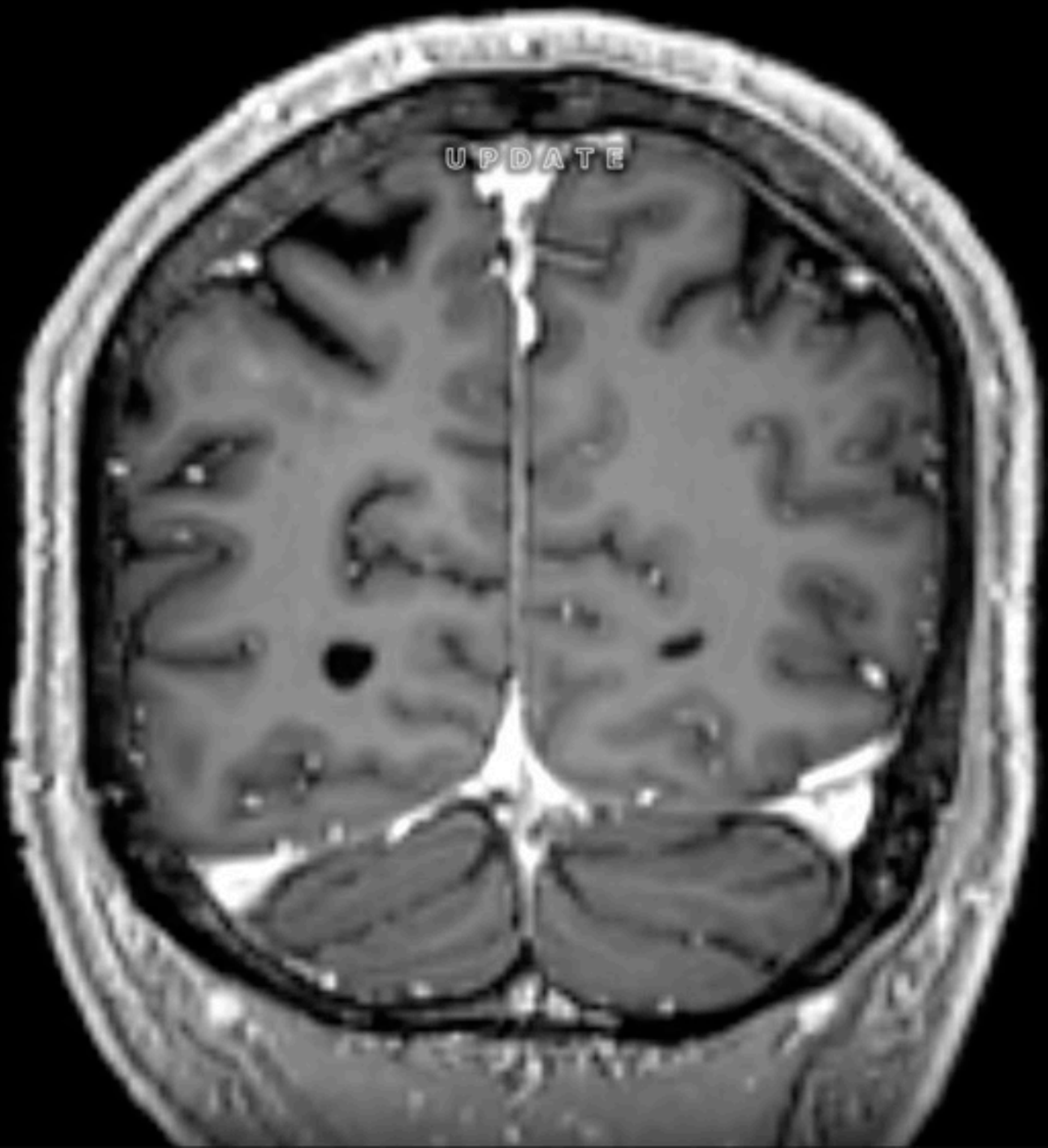

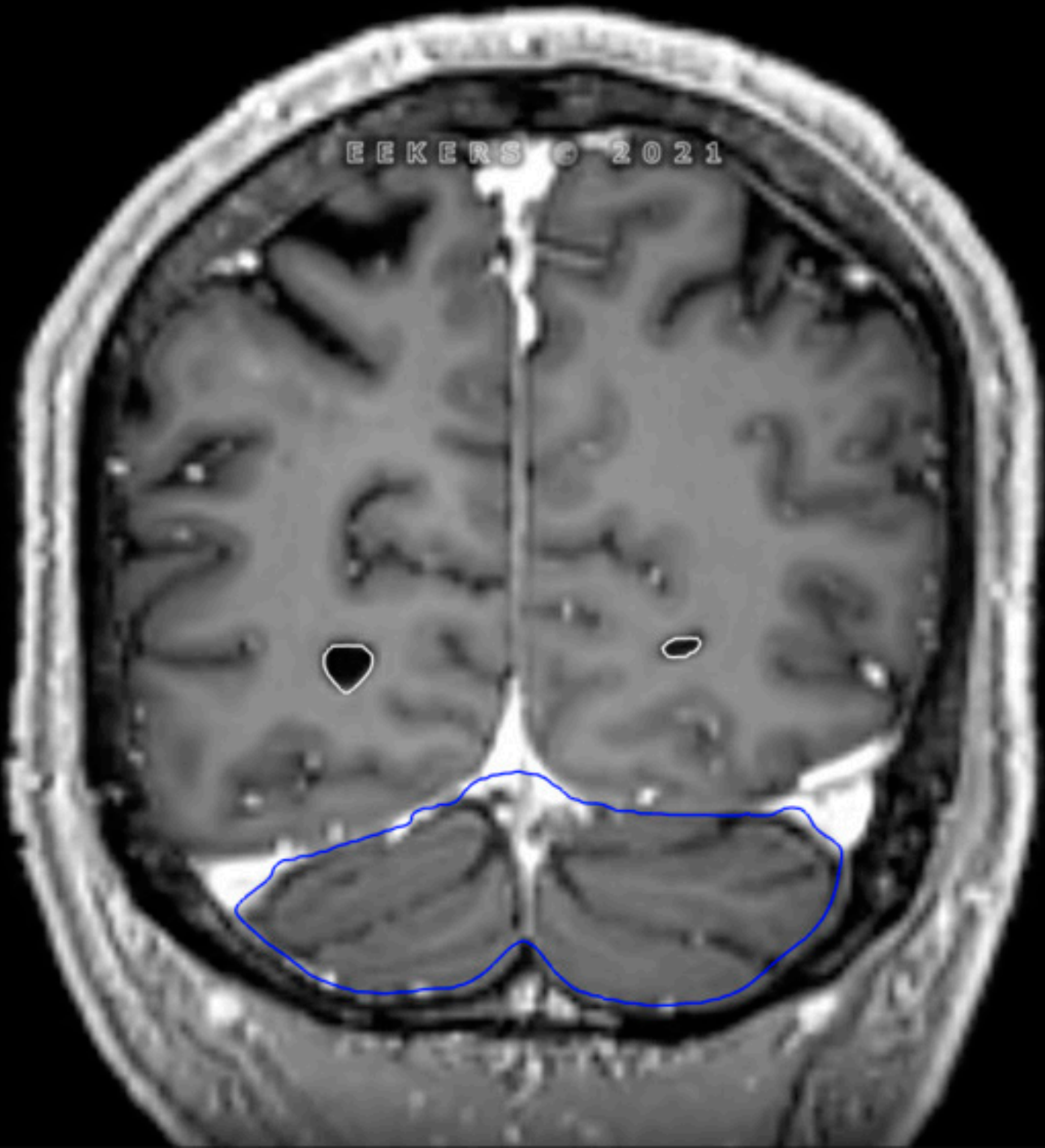
EEKERS © 2021

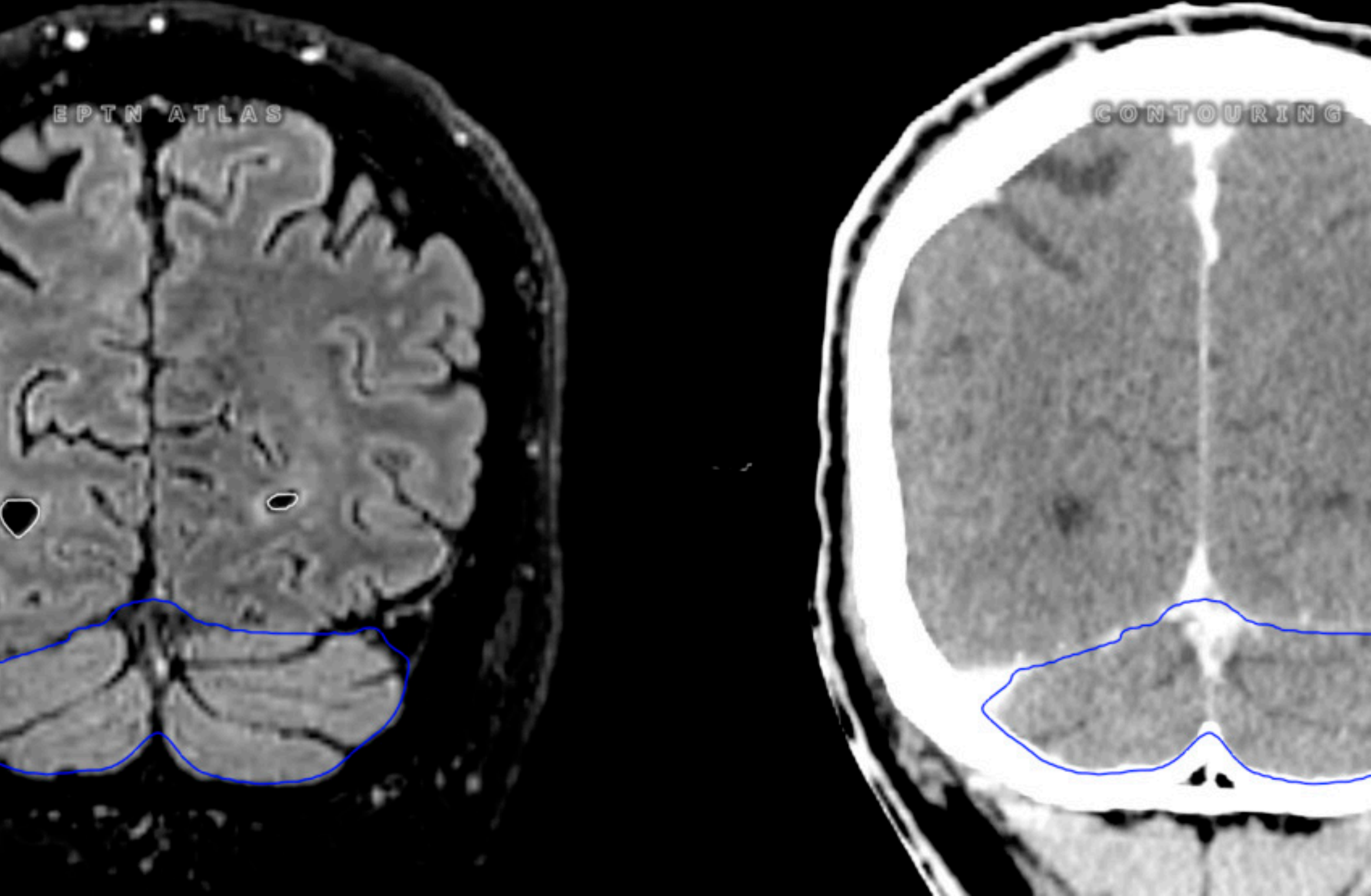
EPTN ATLAS
CONTOURING

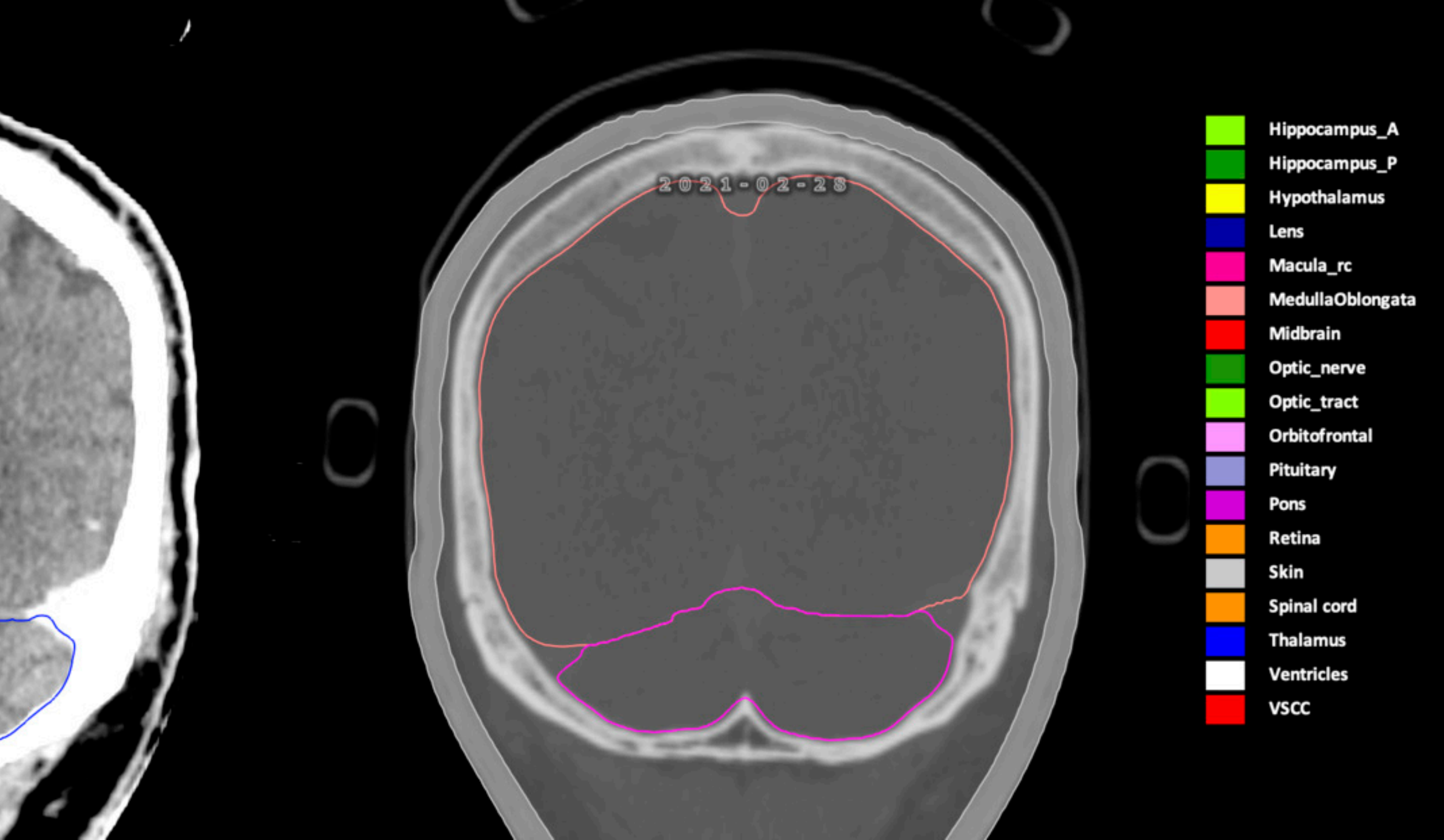
2021-02-28
🟩 Hippocampus_A
🟩 Hippocampus_P
🟨 Hypothalamus
🟦 Lens
🟪 Macula_rc
🟥 MedullaOblongata
🟥 Midbrain
🟩 Optic_nerve
🟩 Optic_tract
🟪 Orbitofrontal
🟪 Pituitary
🟪 Pons
🟧 Retina
⬜ Skin
🟧 Spinal cord
🟦 Thalamus
⬜ Ventricles
🟥 VSCC

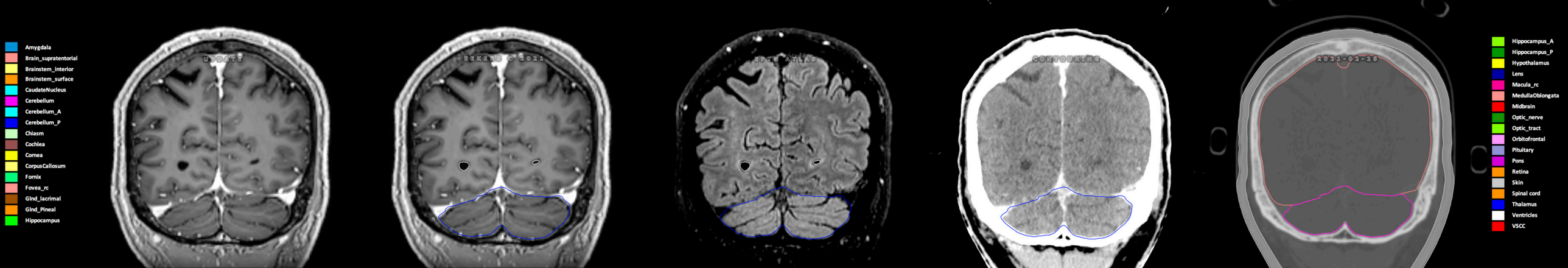
Amygdala
Brain_supratentorial
Brainstem_interior
Brainstem_surface
CaudateNucleus
Cerebellum
Cerebellum_A
Cerebellum_P
Chiasm
Cochlea
Cornea
CorpusCallosum
Fornix
Fovea_rc
Glnd_lacrimal
Glnd_Pineal
Hippocampus
UPDATE
BEKENEL © 2021
EPTS ATLAS
CONTOURING
2021-02-28
Hippocampus_A
Hippocampus_P
Hypothalamus
Lens
Macula_rc
MedullaOblongata
Midbrain
Optic_nerve
Optic_tract
Orbitofrontal
Pituitary
Pons
Retina
Skin
Spinal cord
Thalamus
Ventricles
VSCC

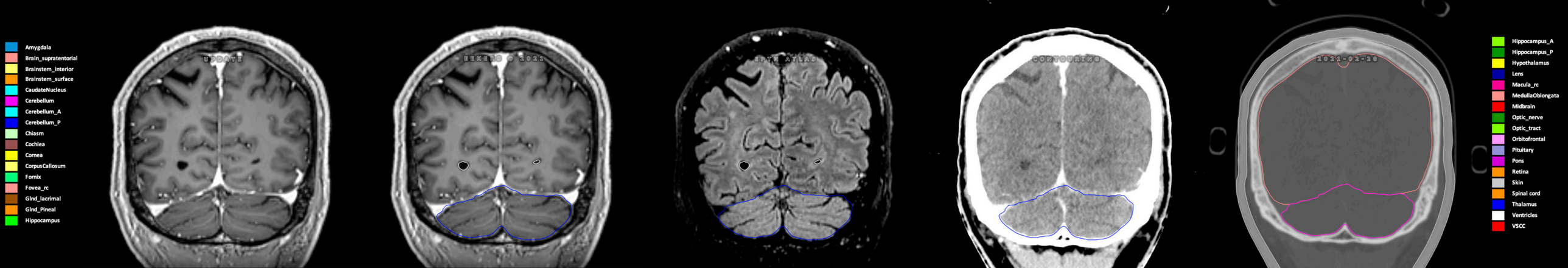
Amygdala
Brain_supratentorial
Brainstem_interior
Brainstem_surface
CaudateNucleus
Cerebellum
Cerebellum_A
Cerebellum_P
Chiasm
Cochlea
Cornea
CorpusCallosum
Fornix
Fovea_rc
Glnd_lacrimal
Glnd_Pineal
Hippocampus
UPDATE
EIKEN © 2021
EPTN ATLAS
CONTOURING
2021-02-28
Hippocampus_A
Hippocampus_P
Hypothalamus
Lens
Macula_rc
MedullaOblongata
Midbrain
Optic_nerve
Optic_tract
Orbitofrontal
Pituitary
Pons
Retina
Skin
Spinal cord
Thalamus
Ventricles
VSCC

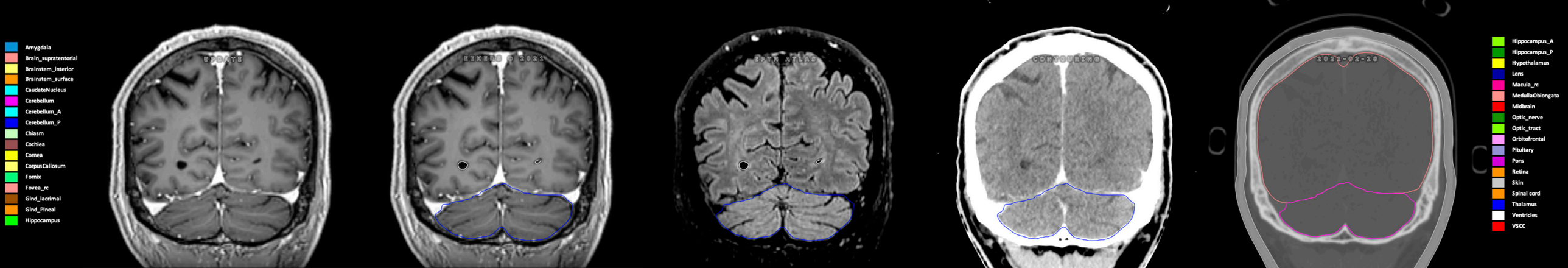
Amygdala
Brain_supratentorial
Brainstem_interior
Brainstem_surface
CaudateNucleus
Cerebellum
Cerebellum_A
Cerebellum_P
Chiasm
Cochlea
Cornea
CorpusCallosum
Fornix
Fovea_rc
Glnd_lacrimal
Glnd_Pineal
Hippocampus
UPDATE
EEKEREN © 2021
EPTE ATLAS
CONTOURING
2021-02-28
Hippocampus_A
Hippocampus_P
Hypothalamus
Lens
Macula_rc
MedullaOblongata
Midbrain
Optic_nerve
Optic_tract
Orbitofrontal
Pituitary
Pons
Retina
Skin
Spinal cord
Thalamus
Ventricles
VSCC

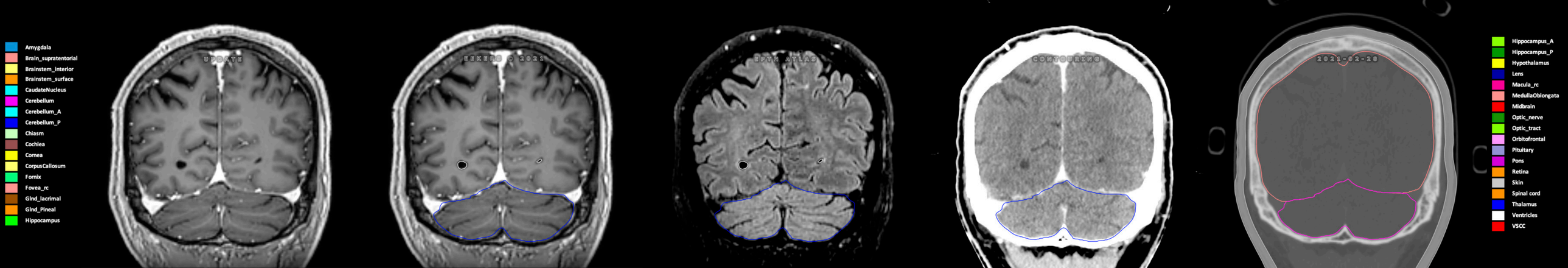
Amygdala
Brain_supratentorial
Brainstem_interior
Brainstem_surface
CaudateNucleus
Cerebellum
Cerebellum_A
Cerebellum_P
Chiasm
Cochlea
Cornea
CorpusCallosum
Fornix
Fovea_rc
Glnd_lacrimal
Glnd_Pineal
Hippocampus
UPDATE
EPTN ATLAS
CONTOURING
2021-02-26
Hippocampus_A
Hippocampus_P
Hypothalamus
Lens
Macula_rc
MedullaOblongata
Midbrain
Optic_nerve
Optic_tract
Orbitofrontal
Pituitary
Pons
Retina
Skin
Spinal cord
Thalamus
Ventricles
VSCC

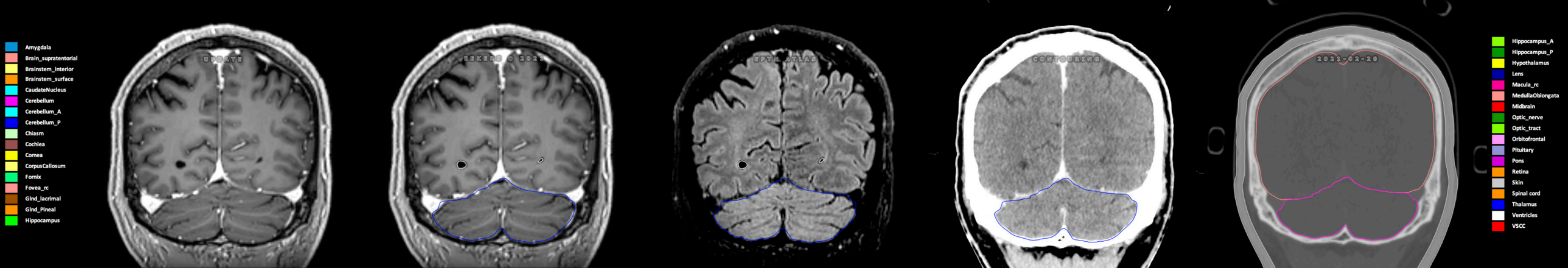
Amygdala
Brain_supratentorial
Brainstem_interior
Brainstem_surface
CaudateNucleus
Cerebellum
Cerebellum_A
Cerebellum_P
Chiasm
Cochlea
Cornea
CorpusCallosum
Fornix
Fovea_rc
Glnd_lacrimal
Glnd_Pineal
Hippocampus
UPDATE
EPTA ATLAS
CONTOURING
2021-02-26
Hippocampus_A
Hippocampus_P
Hypothalamus
Lens
Macula_rc
MedullaOblongata
Midbrain
Optic_nerve
Optic_tract
Orbitofrontal
Pituitary
Pons
Retina
Skin
Spinal cord
Thalamus
Ventricles
VSCC

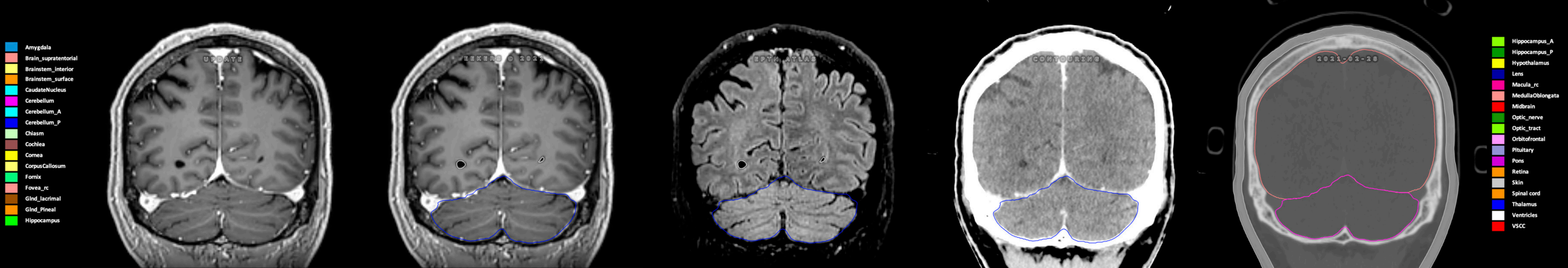
Amygdala
Brain_supratentorial
Brainstem_interior
Brainstem_surface
CaudateNucleus
Cerebellum
Cerebellum_A
Cerebellum_P
Chiasm
Cochlea
Cornea
CorpusCallosum
Fornix
Fovea_rc
Glnd_lacrimal
Glnd_Pineal
Hippocampus
UPDATE
LEKENS © 2021
EPTN ATLAS
CONTOURING
2021-02-28
Hippocampus_A
Hippocampus_P
Hypothalamus
Lens
Macula_rc
MedullaOblongata
Midbrain
Optic_nerve
Optic_tract
Orbitofrontal
Pituitary
Pons
Retina
Skin
Spinal cord
Thalamus
Ventricles
VSCC

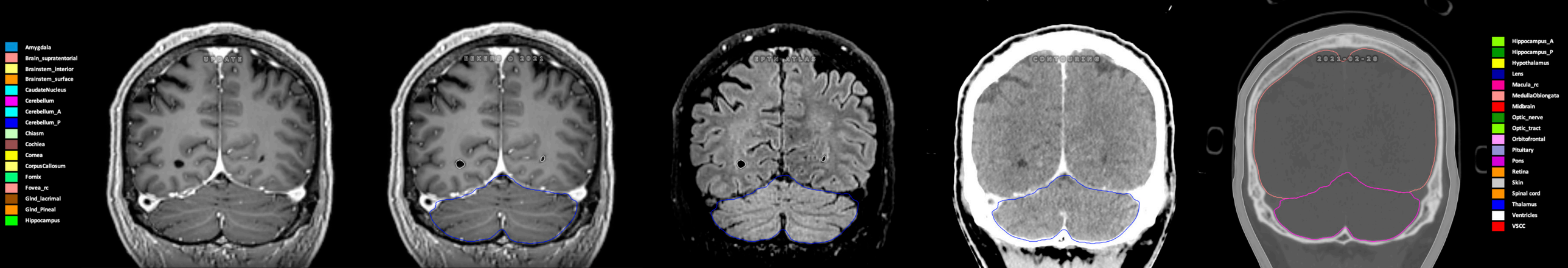
Amygdala
Brain_supratentorial
Brainstem_interior
Brainstem_surface
CaudateNucleus
Cerebellum
Cerebellum_A
Cerebellum_P
Chiasm
Cochlea
Cornea
CorpusCallosum
Fornix
Fovea_rc
Gland_lacrimal
Gland_Pineal
Hippocampus
UPDATE
EKEHR © 2021
UPDATE ATLAS
CONTOURING
2021-02-28
Hippocampus_A
Hippocampus_P
Hypothalamus
Lens
Macula_rc
MedullaOblongata
Midbrain
Optic_nerve
Optic_tract
Orbitofrontal
Pituitary
Pons
Retina
Skin
Spinal cord
Thalamus
Ventricles
VSCC

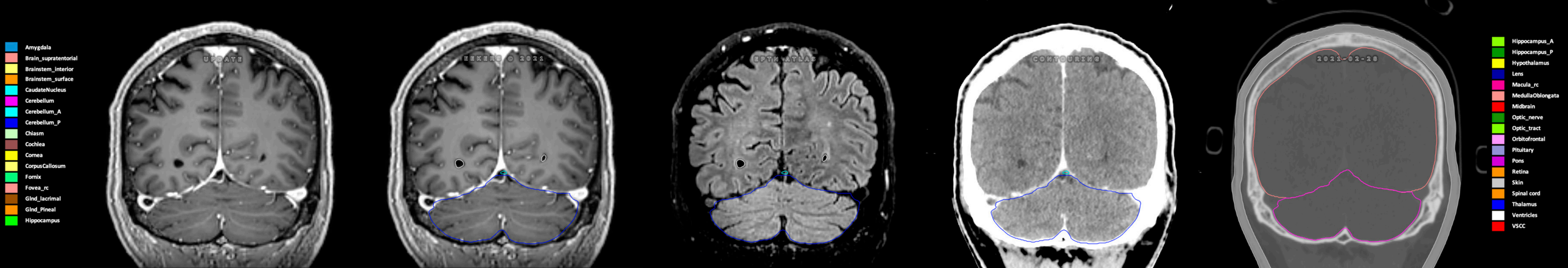
Amygdala
Brain_supratentorial
Brainstem_interior
Brainstem_surface
CaudateNucleus
Cerebellum
Cerebellum_A
Cerebellum_P
Chiasm
Cochlea
Cornea
CorpusCallosum
Fornix
Fovea_rc
Glnd_lacrimal
Glnd_Pineal
Hippocampus
UPDATE
EPTN ATLAS
CONTOURING
2021-02-28
Hippocampus_A
Hippocampus_P
Hypothalamus
Lens
Macula_rc
MedullaOblongata
Midbrain
Optic_nerve
Optic_tract
Orbitofrontal
Pituitary
Pons
Retina
Skin
Spinal cord
Thalamus
Ventricles
VSCC

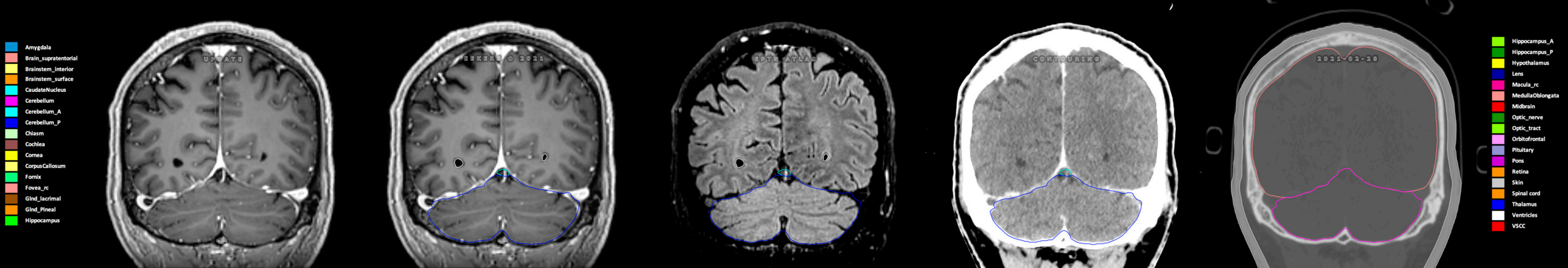
Amygdala
Brain_supratentorial
Brainstem_interior
Brainstem_surface
CaudateNucleus
Cerebellum
Cerebellum_A
Cerebellum_P
Chiasm
Cochlea
Cornea
CorpusCallosum
Fornix
Fovea_rc
Glnd_lacrimal
Glnd_Pineal
Hippocampus
UPDATE
UPDATE ATLAS
CONTOURING
2021-02-28
Hippocampus_A
Hippocampus_P
Hypothalamus
Lens
Macula_rc
MedullaOblongata
Midbrain
Optic_nerve
Optic_tract
Orbitofrontal
Pituitary
Pons
Retina
Skin
Spinal cord
Thalamus
Ventricles
VSCC

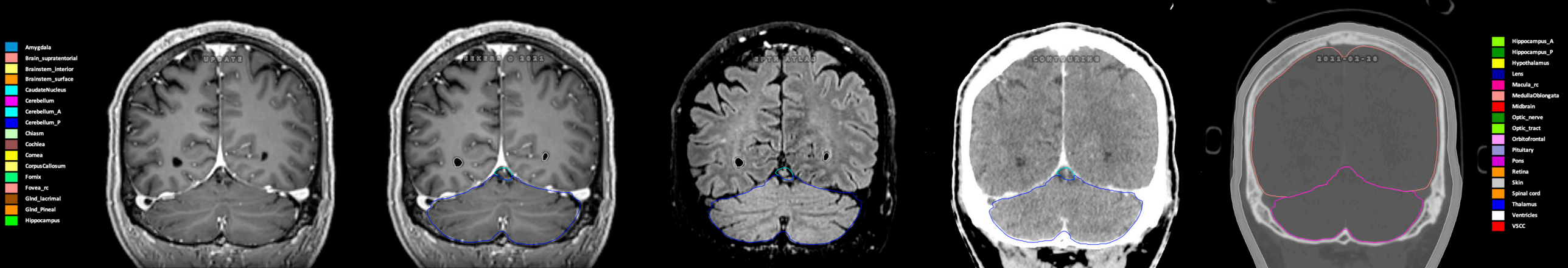
Amygdala
Brain_supratentorial
Brainstem_interior
Brainstem_surface
CaudateNucleus
Cerebellum
Cerebellum_A
Cerebellum_P
Chiasm
Cochlea
Cornea
CorpusCallosum
Fornix
Fovea_rc
Glnd_lacrimal
Glnd_Pineal
Hippocampus
UPDATE
EKEKS © 2021
EPTS ATLAS
CONTOURING
2021-02-28
Hippocampus_A
Hippocampus_P
Hypothalamus
Lens
Macula_rc
MedullaOblongata
Midbrain
Optic_nerve
Optic_tract
Orbitofrontal
Pituitary
Pons
Retina
Skin
Spinal cord
Thalamus
Ventricles
VSCC

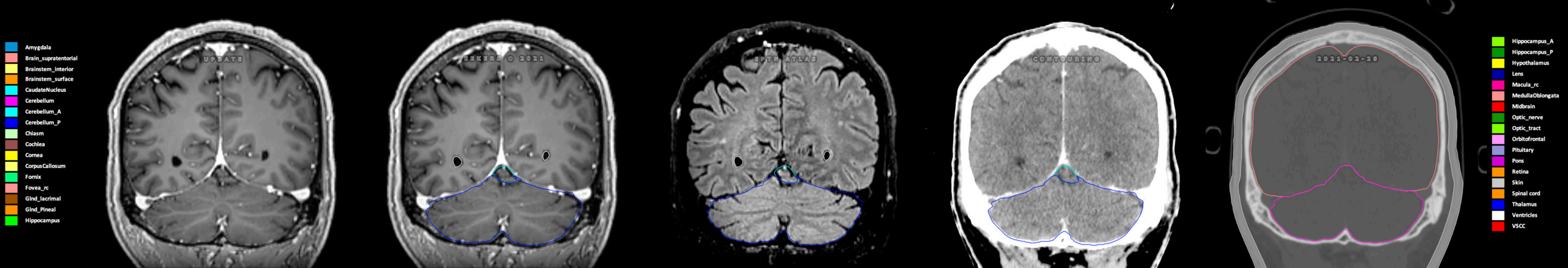
Amygdala
Brain_supratentorial
Brainstem_interior
Brainstem_surface
CaudateNucleus
Cerebellum
Cerebellum_A
Cerebellum_P
Chiasm
Cochlea
Cornea
CorpusCallosum
Fornix
Fovea_rc
Glnd_lacrimal
Glnd_Pineal
Hippocampus
UPSATE
EEKERS © 2021
EPTE ATLAS
CONTOURING
2021-02-28
Hippocampus_A
Hippocampus_P
Hypothalamus
Lens
Macula_rc
MedullaOblongata
Midbrain
Optic_nerve
Optic_tract
Orbitofrontal
Pituitary
Pons
Retina
Skin
Spinal cord
Thalamus
Ventricles
VSCC

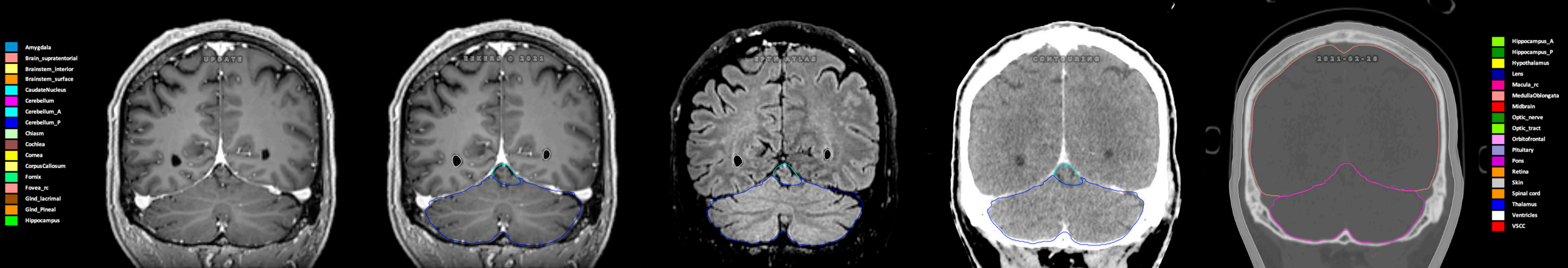
Amygdala
Brain_supratentorial
Brainstem_interior
Brainstem_surface
CaudateNucleus
Cerebellum
Cerebellum_A
Cerebellum_P
Chiasm
Cochlea
Cornea
CorpusCallosum
Fornix
Fovea_rc
Glnd_lacrimal
Glnd_Pineal
Hippocampus
UPSATE
EEKERS © 2021
EPTE ATLAS
CONTOURING
2021-02-28
Hippocampus_A
Hippocampus_P
Hypothalamus
Lens
Macula_rc
MedullaOblongata
Midbrain
Optic_nerve
Optic_tract
Orbitofrontal
Pituitary
Pons
Retina
Skin
Spinal cord
Thalamus
Ventricles
VSCC

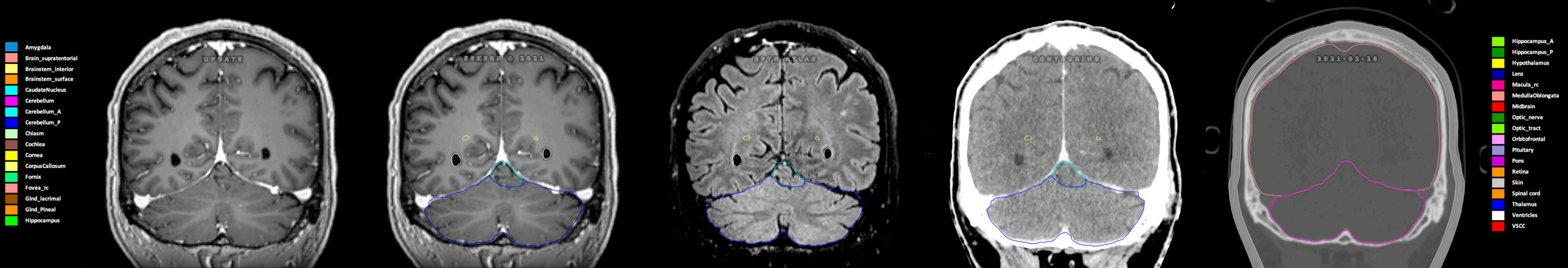
Amygdala
Brain_supratentorial
Brainstem_interior
Brainstem_surface
CaudateNucleus
Cerebellum
Cerebellum_A
Cerebellum_P
Chiasm
Cochlea
Cornea
CorpusCallosum
Fornix
Fovea_rc
Glnd_lacrimal
Glnd_Pineal
Hippocampus
UPSATE
EEKERS © 2021
EPTH ATLAS
CONTOURING
2021-02-28
Hippocampus_A
Hippocampus_P
Hypothalamus
Lens
Macula_rc
MedullaOblongata
Midbrain
Optic_nerve
Optic_tract
Orbitofrontal
Pituitary
Pons
Retina
Skin
Spinal cord
Thalamus
Ventricles
VSCC

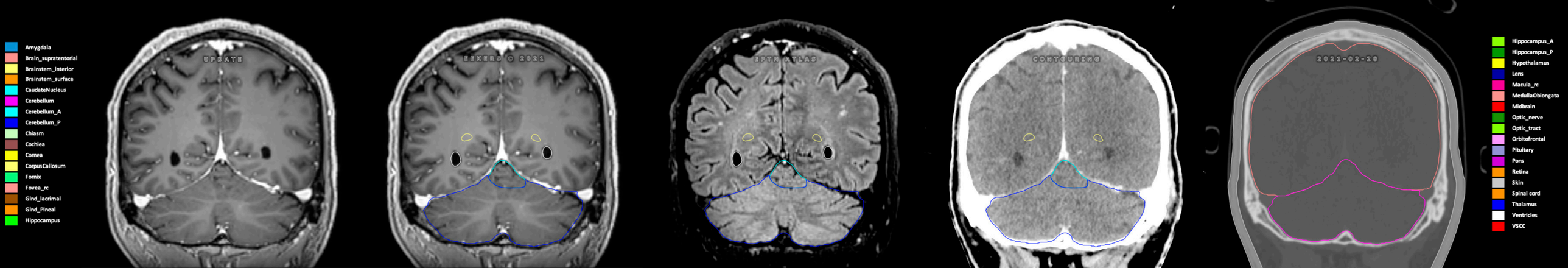
Amygdala
Brain_supratentorial
Brainstem_interior
Brainstem_surface
CaudateNucleus
Cerebellum
Cerebellum_A
Cerebellum_P
Chiasm
Cochlea
Cornea
CorpusCallosum
Fornix
Fovea_rc
Gland_lacrimal
Gland_Pineal
Hippocampus
UPDATE
EEKERC © 2021
EPTN ATLAS
CONTOURING
2021-02-28
Hippocampus_A
Hippocampus_P
Hypothalamus
Lens
Macula_rc
MedullaOblongata
Midbrain
Optic_nerve
Optic_tract
Orbitofrontal
Pituitary
Pons
Retina
Skin
Spinal cord
Thalamus
Ventricles
VSCC

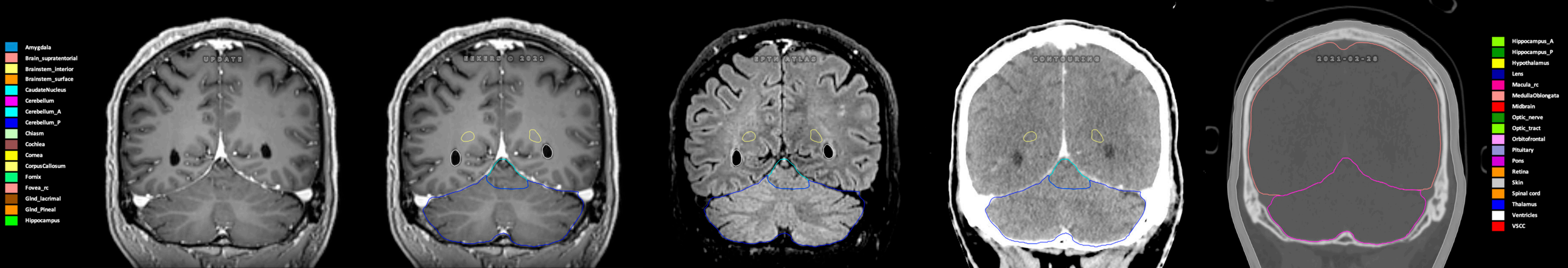
Amygdala
Brain_supratentorial
Brainstem_interior
Brainstem_surface
CaudateNucleus
Cerebellum
Cerebellum_A
Cerebellum_P
Chiasm
Cochlea
Cornea
CorpusCallosum
Fornix
Fovea_rc
Gland_lacrimal
Gland_Pineal
Hippocampus
UPDATE
EKEKO © 2021
EPTN ATLAS
CONTOURING
2021-02-28
Hippocampus_A
Hippocampus_P
Hypothalamus
Lens
Macula_rc
MedullaOblongata
Midbrain
Optic_nerve
Optic_tract
Orbitofrontal
Pituitary
Pons
Retina
Skin
Spinal cord
Thalamus
Ventricles
VSCC

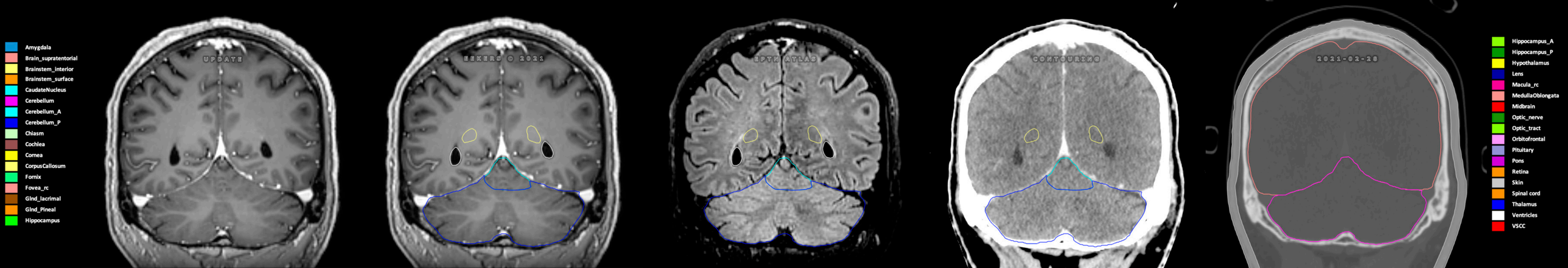
Amygdala
Brain_supratentorial
Brainstem_interior
Brainstem_surface
CaudateNucleus
Cerebellum
Cerebellum_A
Cerebellum_P
Chiasm
Cochlea
Cornea
CorpusCallosum
Fornix
Fovea_rc
Glnd_lacrimal
Glnd_Pineal
Hippocampus
UPDATE
EEKERO © 2021
EPTH ATLAS
CONTOURING
2021-02-28
Hippocampus_A
Hippocampus_P
Hypothalamus
Lens
Macula_rc
MedullaOblongata
Midbrain
Optic_nerve
Optic_tract
Orbitofrontal
Pituitary
Pons
Retina
Skin
Spinal cord
Thalamus
Ventricles
VSCC

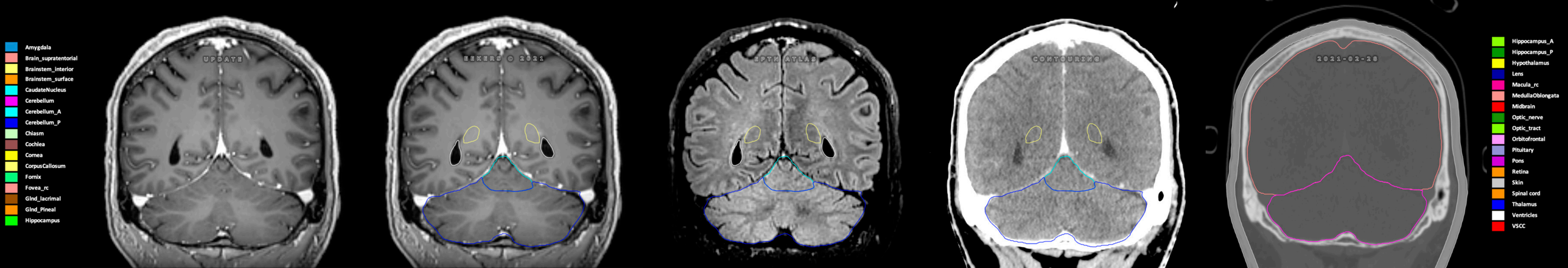
Amygdala
Brain_supratentorial
Brainstem_interior
Brainstem_surface
CaudateNucleus
Cerebellum
Cerebellum_A
Cerebellum_P
Chiasm
Cochlea
Cornea
CorpusCallosum
Fornix
Fovea_rc
Glnd_lacrimal
Glnd_Pineal
Hippocampus
UPDATE
EKERS © 2021
EPTH ATLAS
CONTOURING
2021-02-28
Hippocampus_A
Hippocampus_P
Hypothalamus
Lens
Macula_rc
MedullaOblongata
Midbrain
Optic_nerve
Optic_tract
Orbitofrontal
Pituitary
Pons
Retina
Skin
Spinal cord
Thalamus
Ventricles
VSCC

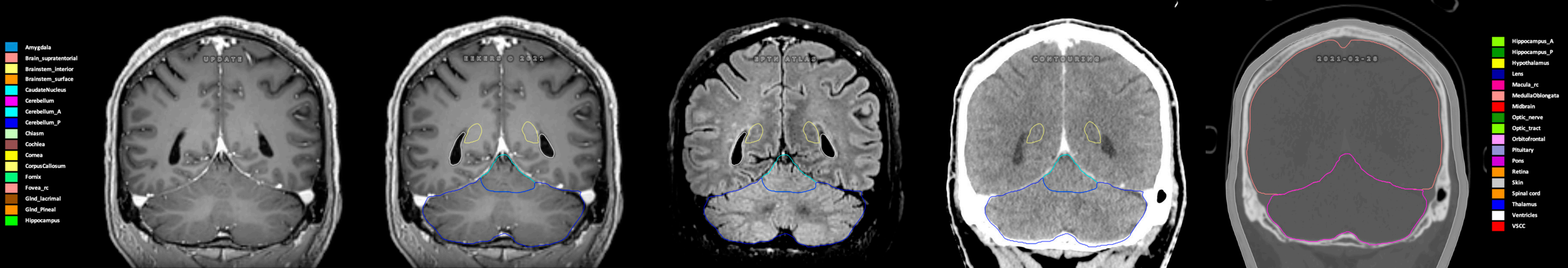
Amygdala
Brain_supratentorial
Brainstem_interior
Brainstem_surface
CaudateNucleus
Cerebellum
Cerebellum_A
Cerebellum_P
Chiasm
Cochlea
Cornea
CorpusCallosum
Fornix
Fovea_rc
Glnd_lacrimal
Glnd_Pineal
Hippocampus
UPDATE
EKERS © 2021
EPTH ATLAS
CONTOURING
2021-02-28
Hippocampus_A
Hippocampus_P
Hypothalamus
Lens
Macula_rc
MedullaOblongata
Midbrain
Optic_nerve
Optic_tract
Orbitofrontal
Pituitary
Pons
Retina
Skin
Spinal cord
Thalamus
Ventricles
VSCC

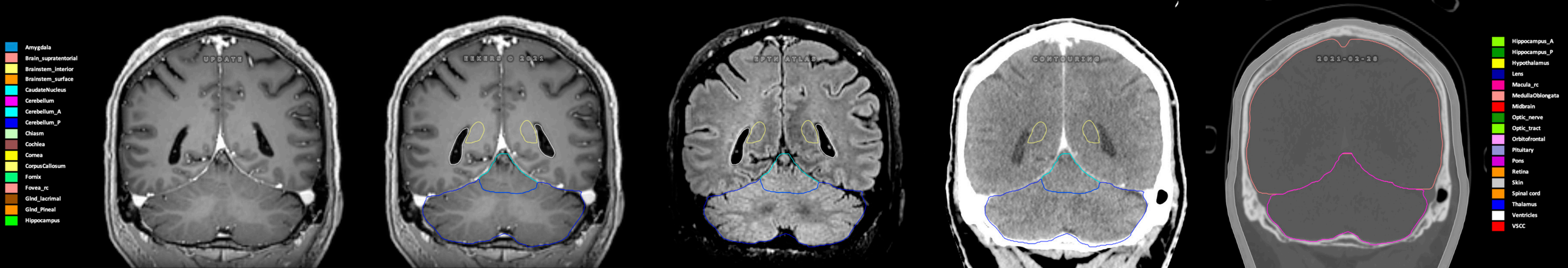
Amygdala
Brain_supratentorial
Brainstem_interior
Brainstem_surface
CaudateNucleus
Cerebellum
Cerebellum_A
Cerebellum_P
Chiasm
Cochlea
Cornea
CorpusCallosum
Fornix
Fovea_rc
Glnd_lacrimal
Glnd_Pineal
Hippocampus
UPDATE
EKERS © 2021
EPTH ATLAS
CONTOURING
2021-02-28
Hippocampus_A
Hippocampus_P
Hypothalamus
Lens
Macula_rc
MedullaOblongata
Midbrain
Optic_nerve
Optic_tract
Orbitofrontal
Pituitary
Pons
Retina
Skin
Spinal cord
Thalamus
Ventricles
VSCC

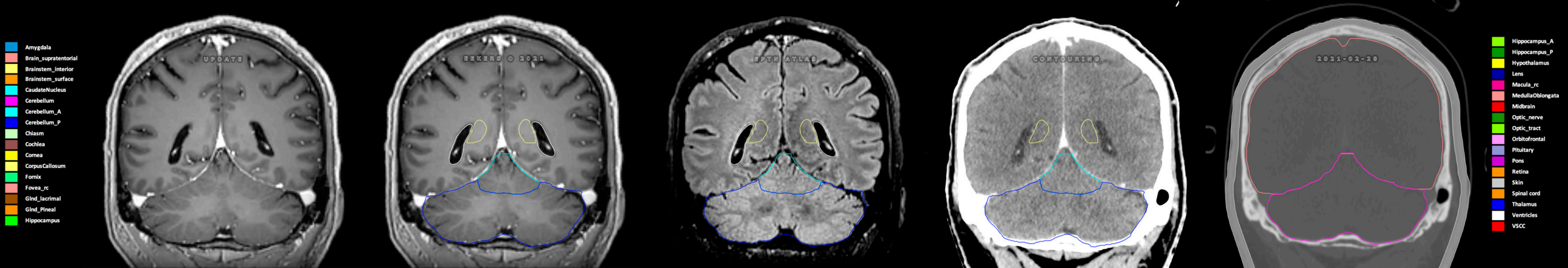
Amygdala
Brain_supratentorial
Brainstem_interior
Brainstem_surface
CaudateNucleus
Cerebellum
Cerebellum_A
Cerebellum_P
Chiasm
Cochlea
Cornea
CorpusCallosum
Fornix
Fovea_rc
Glnd_lacrimal
Glnd_Pineal
Hippocampus
UPDATE
EEKERS © 2021
EPTN ATLAS
CONTOURING
2021-02-28
Hippocampus_A
Hippocampus_P
Hypothalamus
Lens
Macula_rc
MedullaOblongata
Midbrain
Optic_nerve
Optic_tract
Orbitofrontal
Pituitary
Pons
Retina
Skin
Spinal cord
Thalamus
Ventricles
VSCC

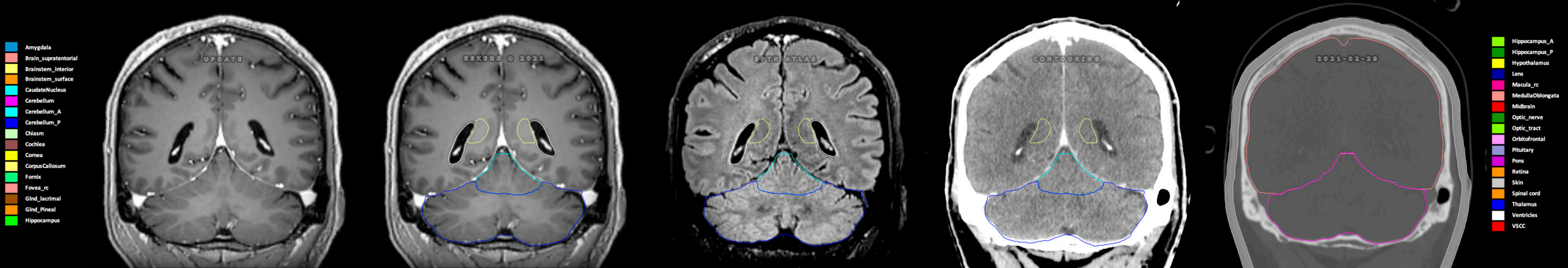
Amygdala
Brain_supratentorial
Brainstem_interior
Brainstem_surface
CaudateNucleus
Cerebellum
Cerebellum_A
Cerebellum_P
Chiasm
Cochlea
Cornea
CorpusCallosum
Fornix
Fovea_rc
Glnd_lacrimal
Glnd_Pineal
Hippocampus
UPDATE
EEKERS © 2021
EPTN ATLAS
CONTOURING
2021-02-28
Hippocampus_A
Hippocampus_P
Hypothalamus
Lens
Macula_rc
MedullaOblongata
Midbrain
Optic_nerve
Optic_tract
Orbitofrontal
Pituitary
Pons
Retina
Skin
Spinal cord
Thalamus
Ventricles
VSCC

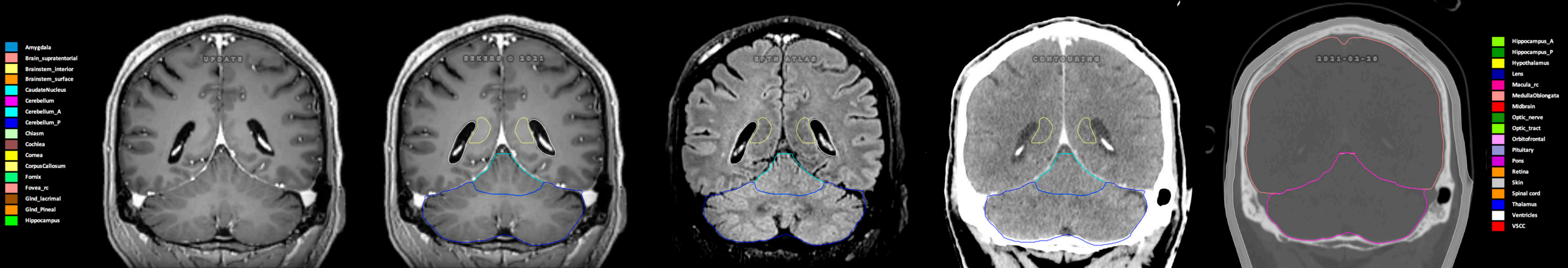
Amygdala
Brain_supratentorial
Brainstem_interior
Brainstem_surface
CaudateNucleus
Cerebellum
Cerebellum_A
Cerebellum_P
Chiasm
Cochlea
Cornea
CorpusCallosum
Fornix
Fovea_rc
Glnd_lacrimal
Glnd_Pineal
Hippocampus
UPDATE
EEKERS © 2021
EPTN ATLAS
CONTOURING
2021-02-28
Hippocampus_A
Hippocampus_P
Hypothalamus
Lens
Macula_rc
MedullaOblongata
Midbrain
Optic_nerve
Optic_tract
Orbitofrontal
Pituitary
Pons
Retina
Skin
Spinal cord
Thalamus
Ventricles
VSCC

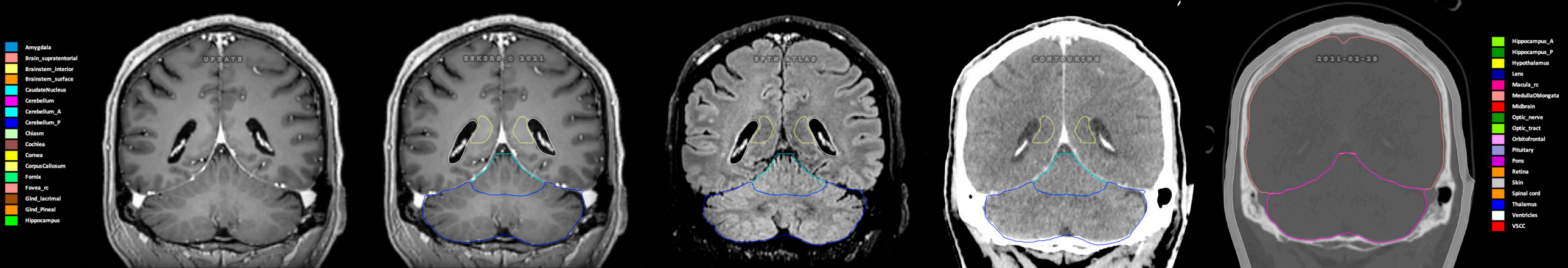
Amygdala
Brain_supratentorial
Brainstem_interior
Brainstem_surface
CaudateNucleus
Cerebellum
Cerebellum_A
Cerebellum_P
Chiasm
Cochlea
Cornea
CorpusCallosum
Fornix
Fovea_rc
Gland_lacrimal
Gland_Pineal
Hippocampus
UPDATE
EKERS © 2021
EPTN ATLAS
CONTOURING
2021-02-28
Hippocampus_A
Hippocampus_P
Hypothalamus
Lens
Macula_rc
MedullaOblongata
Midbrain
Optic_nerve
Optic_tract
Orbitofrontal
Pituitary
Pons
Retina
Skin
Spinal cord
Thalamus
Ventricles
VSCC

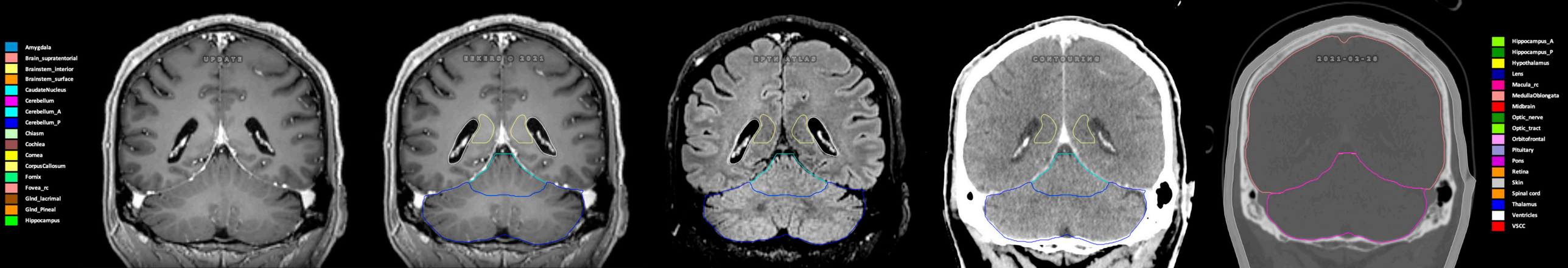
Amygdala
Brain_supratentorial
Brainstem_interior
Brainstem_surface
CaudateNucleus
Cerebellum
Cerebellum_A
Cerebellum_P
Chiasm
Cochlea
Cornea
CorpusCallosum
Fornix
Fovea_rc
Glnd_lacrimal
Glnd_Pineal
Hippocampus
UPDATE
EEKERS © 2021
EPTH ATLAS
CONTOURING
2021-02-28
Hippocampus_A
Hippocampus_P
Hypothalamus
Lens
Macula_rc
MedullaOblongata
Midbrain
Optic_nerve
Optic_tract
Orbitofrontal
Pituitary
Pons
Retina
Skin
Spinal cord
Thalamus
Ventricles
VSCC

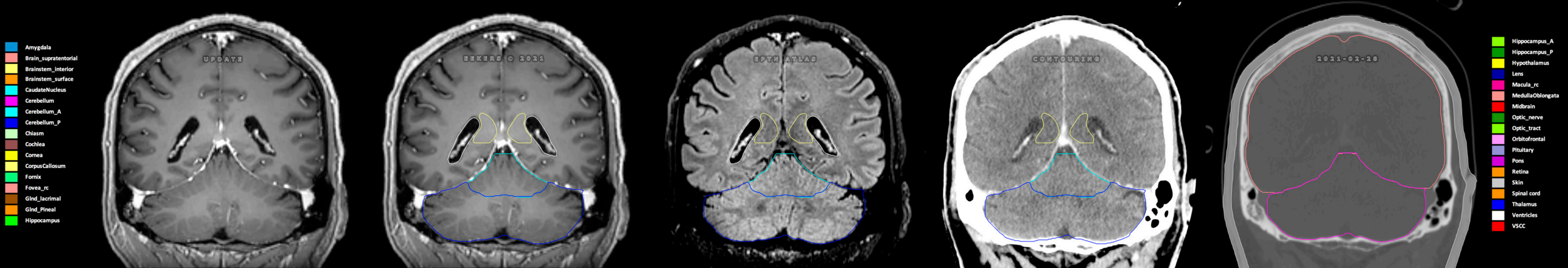
Amygdala
Brain_supratentorial
Brainstem_interior
Brainstem_surface
CaudateNucleus
Cerebellum
Cerebellum_A
Cerebellum_P
Chiasm
Cochlea
Cornea
CorpusCallosum
Fornix
Fovea_rc
Glnd_lacrimal
Glnd_Pineal
Hippocampus
UPDATE
EEKERS © 2021
EPTH ATLAS
CONTOURING
2021-02-28
Hippocampus_A
Hippocampus_P
Hypothalamus
Lens
Macula_rc
MedullaOblongata
Midbrain
Optic_nerve
Optic_tract
Orbitofrontal
Pituitary
Pons
Retina
Skin
Spinal cord
Thalamus
Ventricles
VSCC

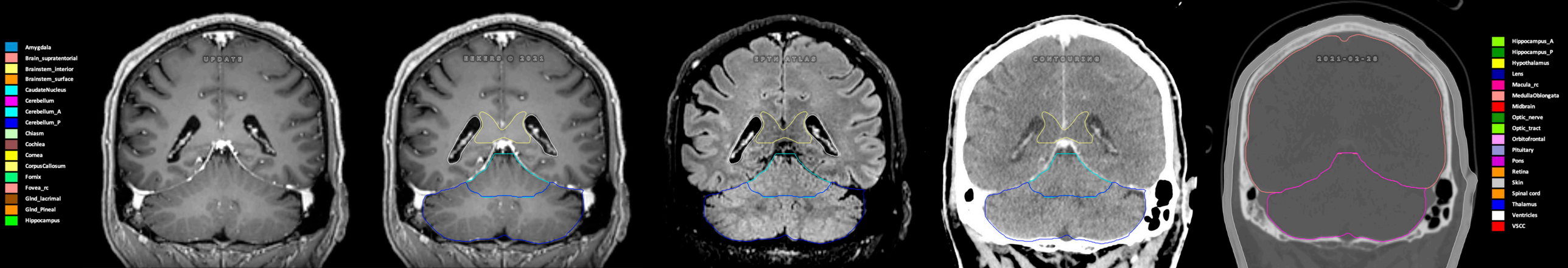
Amygdala
Brain_supratentorial
Brainstem_interior
Brainstem_surface
CaudateNucleus
Cerebellum
Cerebellum_A
Cerebellum_P
Chiasm
Cochlea
Cornea
CorpusCallosum
Fornix
Fovea_rc
Glnd_lacrimal
Glnd_Pineal
Hippocampus
UPDATE
EKERS © 2021
EPTN ATLAS
CONTOURING
2021-02-28
Hippocampus_A
Hippocampus_P
Hypothalamus
Lens
Macula_rc
MedullaOblongata
Midbrain
Optic_nerve
Optic_tract
Orbitofrontal
Pituitary
Pons
Retina
Skin
Spinal cord
Thalamus
Ventricles
VSCC

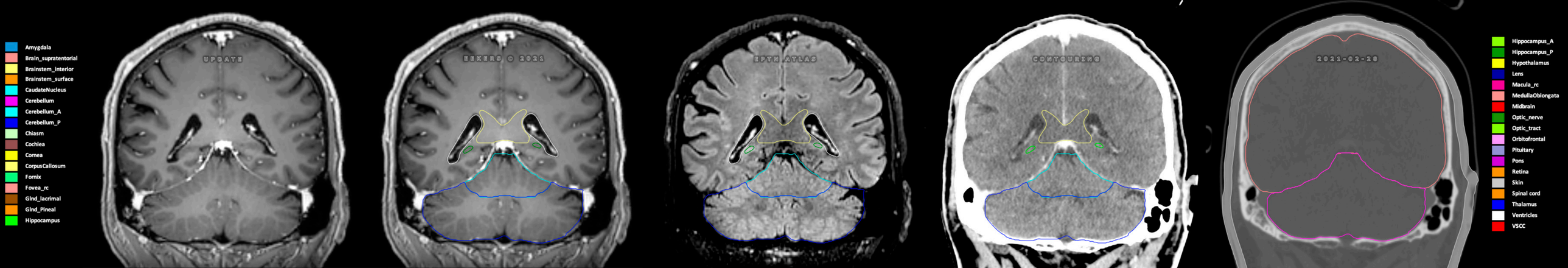
Amygdala
Brain_supratentorial
Brainstem_interior
Brainstem_surface
CaudateNucleus
Cerebellum
Cerebellum_A
Cerebellum_P
Chiasm
Cochlea
Cornea
CorpusCallosum
Fornix
Fovea_rc
Gland_lacrimal
Gland_Pineal
Hippocampus
UPDATE
EKERS © 2021
EPTN ATLAS
CONTOURING
2021-02-28
Hippocampus_A
Hippocampus_P
Hypothalamus
Lens
Macula_rc
MedullaOblongata
Midbrain
Optic_nerve
Optic_tract
Orbitofrontal
Pituitary
Pons
Retina
Skin
Spinal cord
Thalamus
Ventricles
VSCC

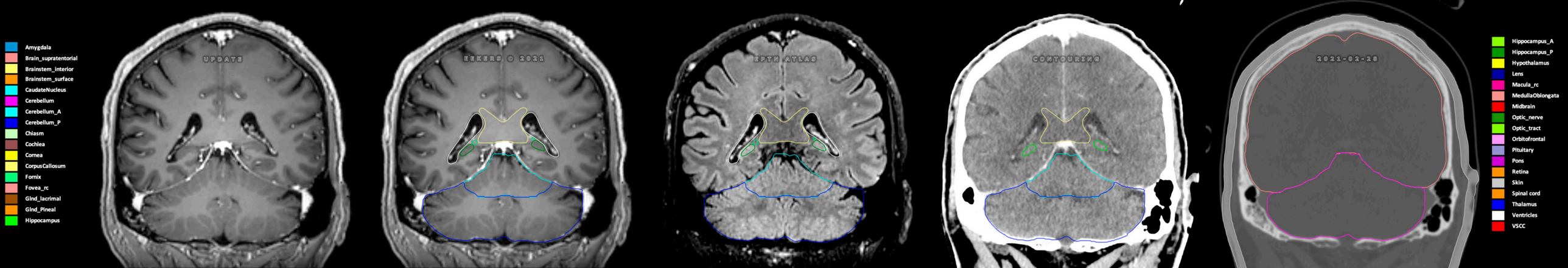
Amygdala
Brain_supratentorial
Brainstem_interior
Brainstem_surface
CaudateNucleus
Cerebellum
Cerebellum_A
Cerebellum_P
Chiasm
Cochlea
Cornea
CorpusCallosum
Fornix
Fovea_rc
Gland_lacrimal
Gland_Pineal
Hippocampus
UPDATE
EKERS © 2021
EPTH ATLAS
CONTOURING
2021-02-28
Hippocampus_A
Hippocampus_P
Hypothalamus
Lens
Macula_rc
MedullaOblongata
Midbrain
Optic_nerve
Optic_tract
Orbitofrontal
Pituitary
Pons
Retina
Skin
Spinal cord
Thalamus
Ventricles
VSCC

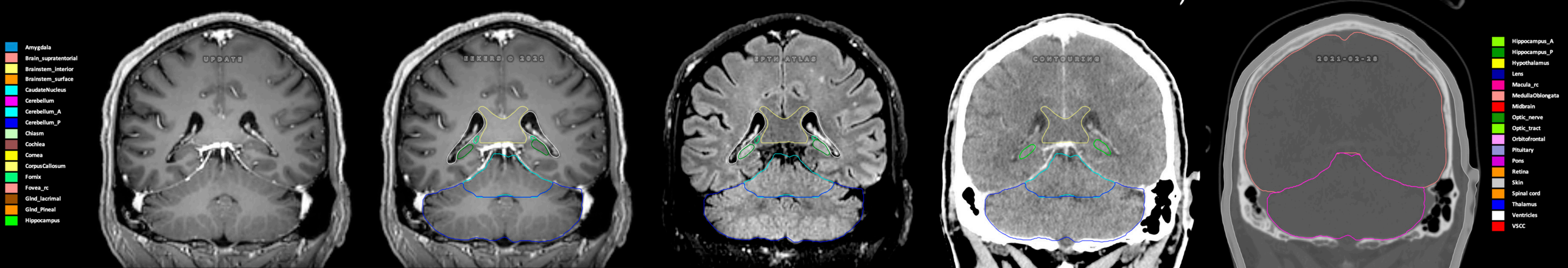
Amygdala
Brain_supratentorial
Brainstem_interior
Brainstem_surface
CaudateNucleus
Cerebellum
Cerebellum_A
Cerebellum_P
Chiasm
Cochlea
Cornea
CorpusCallosum
Fornix
Fovea_rc
Gland_lacrimal
Gland_Pineal
Hippocampus
UPDATE
EKERS © 2021
EPTN ATLAS
CONTOURING
2021-02-28
Hippocampus_A
Hippocampus_P
Hypothalamus
Lens
Macula_rc
MedullaOblongata
Midbrain
Optic_nerve
Optic_tract
Orbitofrontal
Pituitary
Pons
Retina
Skin
Spinal cord
Thalamus
Ventricles
VSCC

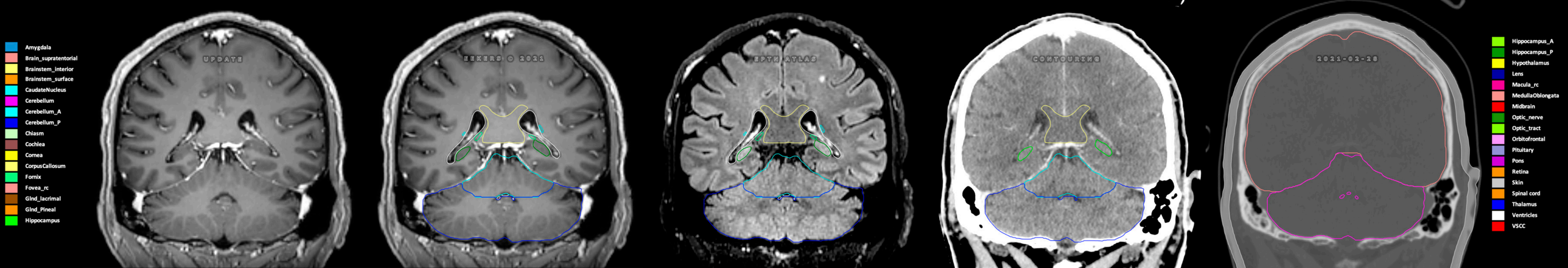
Amygdala
Brain_supratentorial
Brainstem_interior
Brainstem_surface
CaudateNucleus
Cerebellum
Cerebellum_A
Cerebellum_P
Chiasm
Cochlea
Cornea
CorpusCallosum
Fornix
Fovea_rc
Glnd_lacrimal
Glnd_Pineal
Hippocampus
UPDATE
EKERS © 2021
EPTN ATLAS
CONTOURME
2021-02-28
Hippocampus_A
Hippocampus_P
Hypothalamus
Lens
Macula_rc
MedullaOblongata
Midbrain
Optic_nerve
Optic_tract
Orbitofrontal
Pituitary
Pons
Retina
Skin
Spinal cord
Thalamus
Ventricles
VSCC

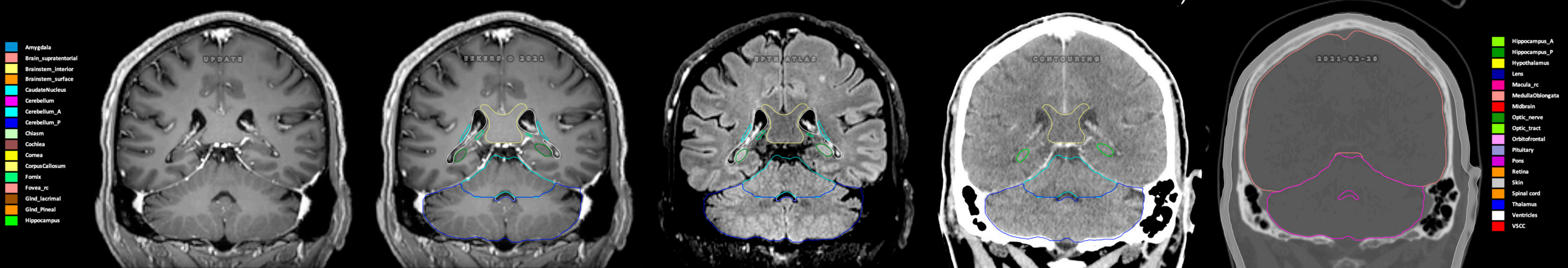
Amygdala
Brain_supratentorial
Brainstem_interior
Brainstem_surface
CaudateNucleus
Cerebellum
Cerebellum_A
Cerebellum_P
Chiasm
Cochlea
Cornea
CorpusCallosum
Fornix
Fovea_rc
Gland_lacrimal
Gland_Pineal
Hippocampus
UPDATE
EEKERS © 2021
EPTH ATLAS
CONTOURING
2021-02-28
Hippocampus_A
Hippocampus_P
Hypothalamus
Lens
Macula_rc
MedullaOblongata
Midbrain
Optic_nerve
Optic_tract
Orbitofrontal
Pituitary
Pons
Retina
Skin
Spinal cord
Thalamus
Ventricles
VSCC

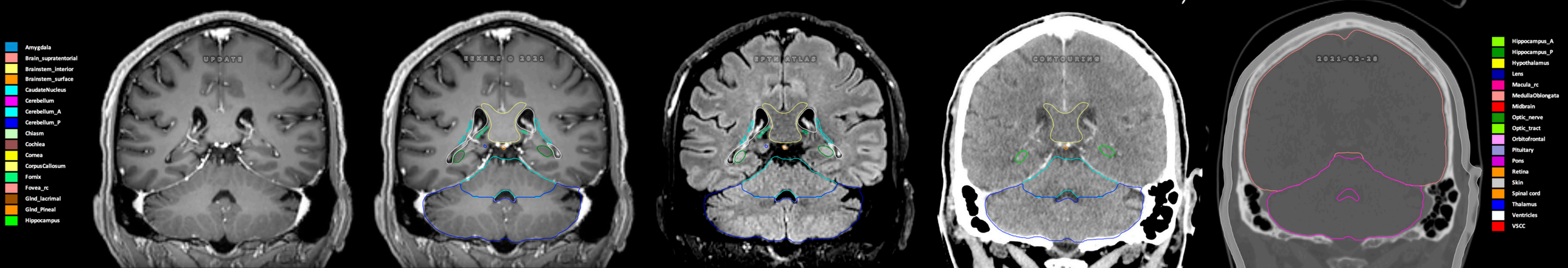
Amygdala
Brain_supratentorial
Brainstem_interior
Brainstem_surface
CaudateNucleus
Cerebellum
Cerebellum_A
Cerebellum_P
Chiasm
Cochlea
Cornea
CorpusCallosum
Fornix
Fovea_rc
Glnd_lacrimal
Glnd_Pineal
Hippocampus
UPDATE
EKERS © 2021
EPTH ATLAS
CONTOURING
2021-02-28
Hippocampus_A
Hippocampus_P
Hypothalamus
Lens
Macula_rc
MedullaOblongata
Midbrain
Optic_nerve
Optic_tract
Orbitofrontal
Pituitary
Pons
Retina
Skin
Spinal cord
Thalamus
Ventricles
VSCC

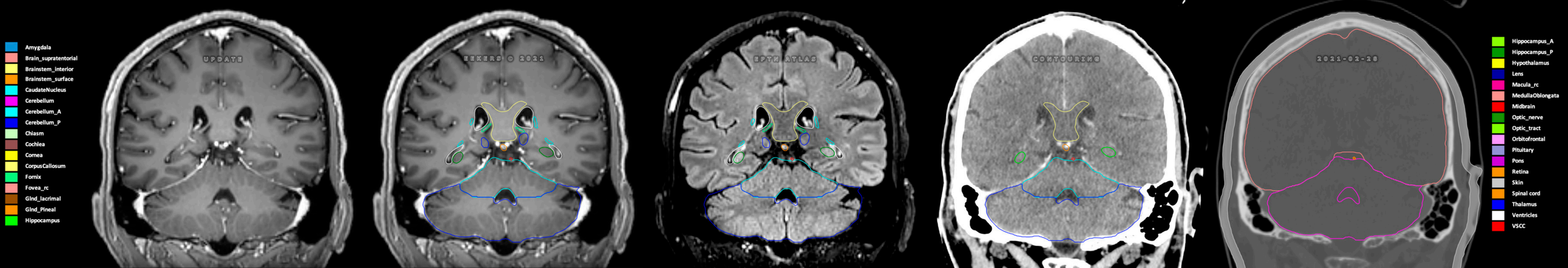
Amygdala
Brain_supratentorial
Brainstem_interior
Brainstem_surface
CaudateNucleus
Cerebellum
Cerebellum_A
Cerebellum_P
Chiasm
Cochlea
Cornea
CorpusCallosum
Fornix
Fovea_rc
Glnd_lacrimal
Glnd_Pineal
Hippocampus
UPDATE
EEKERS © 2021
EPTH ATLAS
CONTOURING
2021-02-28
Hippocampus_A
Hippocampus_P
Hypothalamus
Lens
Macula_rc
MedullaOblongata
Midbrain
Optic_nerve
Optic_tract
Orbitofrontal
Pituitary
Pons
Retina
Skin
Spinal cord
Thalamus
Ventricles
VSCC

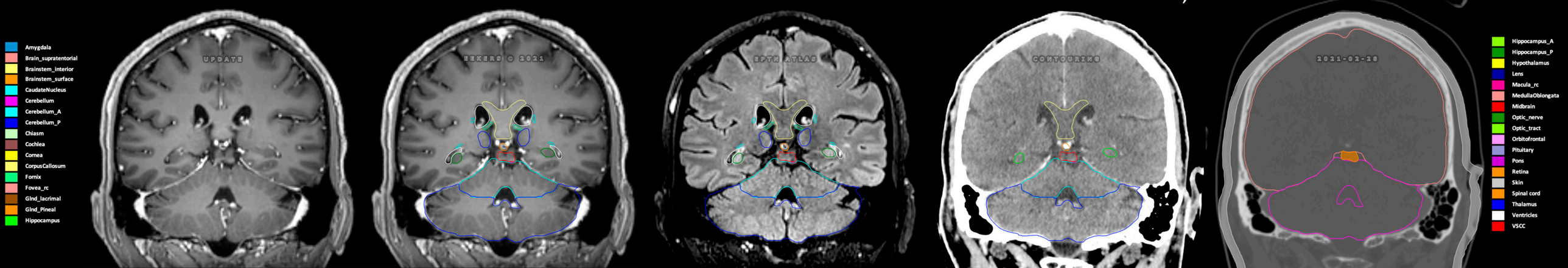
Amygdala
Brain_supratentorial
Brainstem_interior
Brainstem_surface
CaudateNucleus
Cerebellum
Cerebellum_A
Cerebellum_P
Chiasm
Cochlea
Cornea
CorpusCallosum
Fornix
Fovea_rc
Glnd_lacrimal
Glnd_Pineal
Hippocampus
UPDATE
EKERS © 2021
UPTH ATLAS
CONTOURING
2021-02-28
Hippocampus_A
Hippocampus_P
Hypothalamus
Lens
Macula_rc
MedullaOblongata
Midbrain
Optic_nerve
Optic_tract
Orbitofrontal
Pituitary
Pons
Retina
Skin
Spinal cord
Thalamus
Ventricles
VSCC

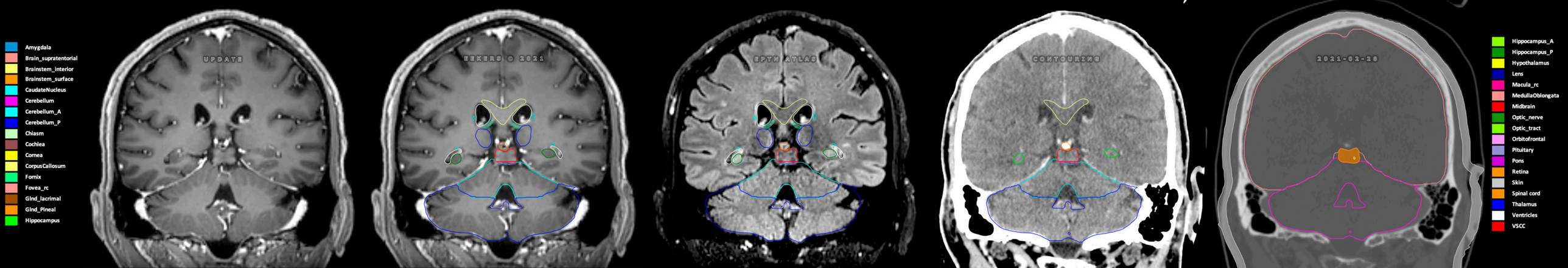
Amygdala
Brain_supratentorial
Brainstem_interior
Brainstem_surface
CaudateNucleus
Cerebellum
Cerebellum_A
Cerebellum_P
Chiasm
Cochlea
Cornea
CorpusCallosum
Fornix
Fovea_rc
Glnd_lacrimal
Glnd_Pineal
Hippocampus
UPDATE
EKERS © 2021
EPTN ATLAS
CONTOURING
2021-02-28
Hippocampus_A
Hippocampus_P
Hypothalamus
Lens
Macula_rc
MedullaOblongata
Midbrain
Optic_nerve
Optic_tract
Orbitofrontal
Pituitary
Pons
Retina
Skin
Spinal cord
Thalamus
Ventricles
VSCC

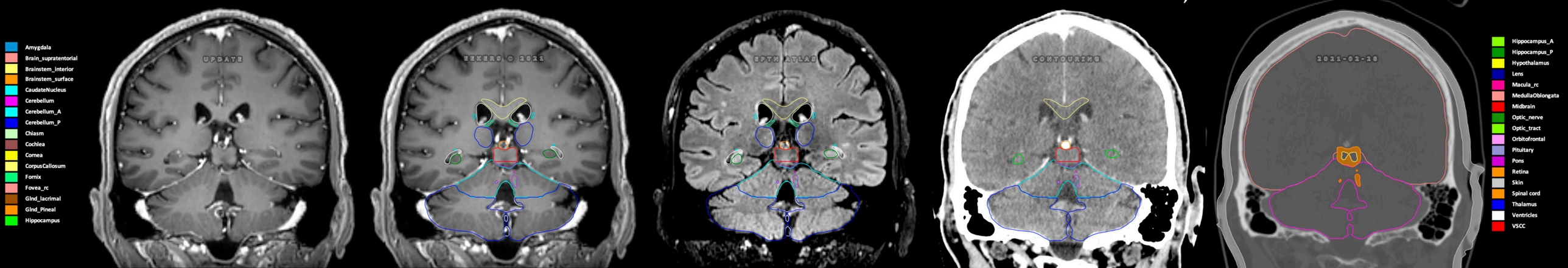
Amygdala
Brain_supratentorial
Brainstem_interior
Brainstem_surface
CaudateNucleus
Cerebellum
Cerebellum_A
Cerebellum_P
Chiasm
Cochlea
Cornea
CorpusCallosum
Fornix
Fovea_rc
Gland_lacrimal
Gland_Pineal
Hippocampus
UPDATE
EEKERS © 2021
EPTN ATLAS
CONTOURING
2021-02-28
Hippocampus_A
Hippocampus_P
Hypothalamus
Lens
Macula_rc
MedullaOblongata
Midbrain
Optic_nerve
Optic_tract
Orbitofrontal
Pituitary
Pons
Retina
Skin
Spinal cord
Thalamus
Ventricles
VSCC

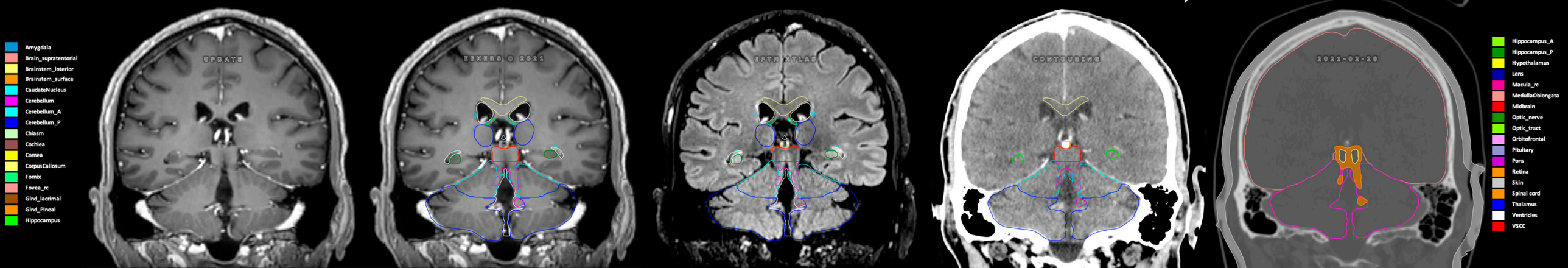
Amygdala
Brain_supratentorial
Brainstem_interior
Brainstem_surface
CaudateNucleus
Cerebellum
Cerebellum_A
Cerebellum_P
Chiasm
Cochlea
Cornea
CorpusCallosum
Fornix
Fovea_rc
Glnd_lacrimal
Glnd_Pineal
Hippocampus
UPDATE
EEKERS © 2021
EPTH ATLAS
CONTOURING
2021-02-28
Hippocampus_A
Hippocampus_P
Hypothalamus
Lens
Macula_rc
MedullaOblongata
Midbrain
Optic_nerve
Optic_tract
Orbitofrontal
Pituitary
Pons
Retina
Skin
Spinal cord
Thalamus
Ventricles
VSCC

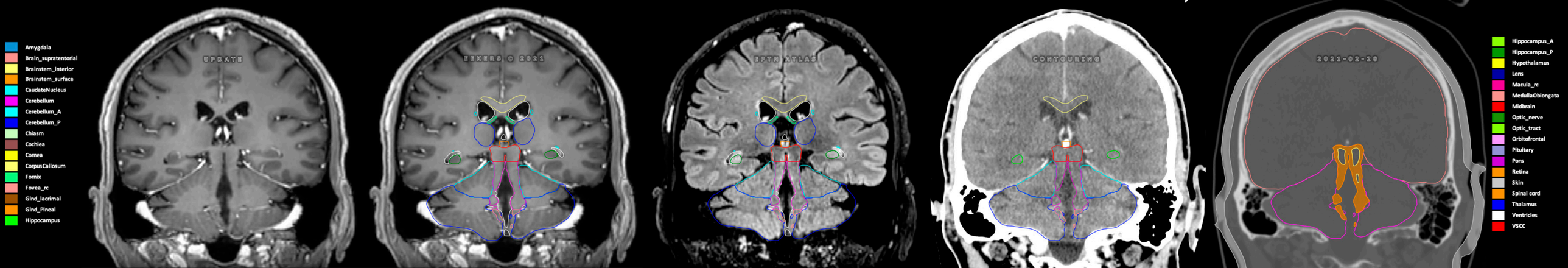
Amygdala
Brain_supratentorial
Brainstem_interior
Brainstem_surface
CaudateNucleus
Cerebellum
Cerebellum_A
Cerebellum_P
Chiasm
Cochlea
Cornea
CorpusCallosum
Fornix
Fovea_rc
Gland_lacrimal
Gland_Pineal
Hippocampus
UPDATE
EKERS © 2021
EPTH ATLAS
CONTOURING
2021-02-28
Hippocampus_A
Hippocampus_P
Hypothalamus
Lens
Macula_rc
MedullaOblongata
Midbrain
Optic_nerve
Optic_tract
Orbitofrontal
Pituitary
Pons
Retina
Skin
Spinal cord
Thalamus
Ventricles
VSCC

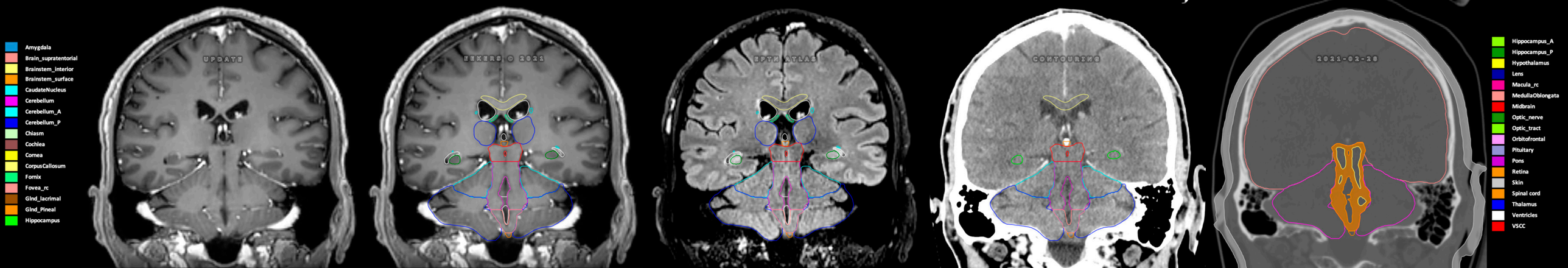
Amygdala
Brain_supratentorial
Brainstem_interior
Brainstem_surface
CaudateNucleus
Cerebellum
Cerebellum_A
Cerebellum_P
Chiasm
Cochlea
Cornea
CorpusCallosum
Fornix
Fovea_rc
Glnd_lacrimal
Glnd_Pineal
Hippocampus
UPDATE
EEKERS © 2021
EPTN ATLAS
CONTOURING
2021-02-28
Hippocampus_A
Hippocampus_P
Hypothalamus
Lens
Macula_rc
MedullaOblongata
Midbrain
Optic_nerve
Optic_tract
Orbitofrontal
Pituitary
Pons
Retina
Skin
Spinal cord
Thalamus
Ventricles
VSCC

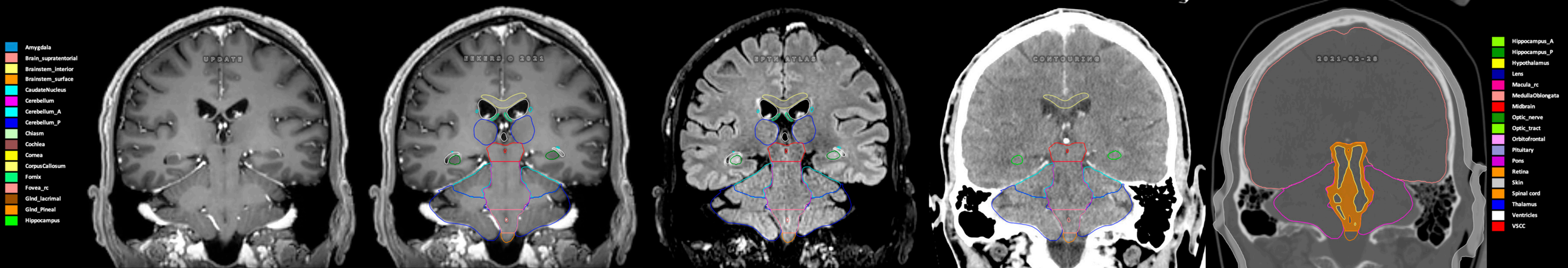
Amygdala
Brain_supratentorial
Brainstem_interior
Brainstem_surface
CaudateNucleus
Cerebellum
Cerebellum_A
Cerebellum_P
Chiasm
Cochlea
Cornea
CorpusCallosum
Fornix
Fovea_rc
Glnd_lacrimal
Glnd_Pineal
Hippocampus
UPDATE
EEKERS © 2021
EPTH ATLAS
CONTOURING
2021-02-28
Hippocampus_A
Hippocampus_P
Hypothalamus
Lens
Macula_rc
MedullaOblongata
Midbrain
Optic_nerve
Optic_tract
Orbitofrontal
Pituitary
Pons
Retina
Skin
Spinal cord
Thalamus
Ventricles
VSCC

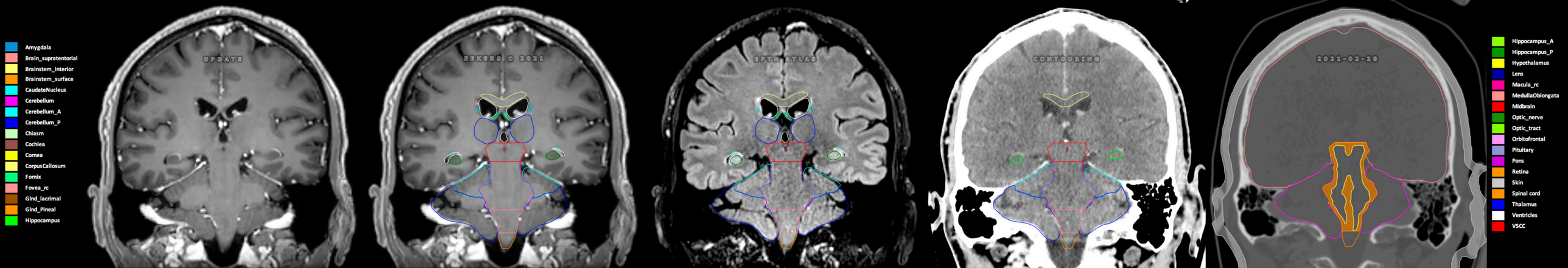
Amygdala
Brain_supratentorial
Brainstem_interior
Brainstem_surface
CaudateNucleus
Cerebellum
Cerebellum_A
Cerebellum_P
Chiasm
Cochlea
Cornea
CorpusCallosum
Fornix
Fovea_rc
Glnd_lacrimal
Glnd_Pineal
Hippocampus
UPDATE
EEKERS © 2021
EPTH ATLAS
CONTOURING
2021-02-28
Hippocampus_A
Hippocampus_P
Hypothalamus
Lens
Macula_rc
MedullaOblongata
Midbrain
Optic_nerve
Optic_tract
Orbitofrontal
Pituitary
Pons
Retina
Skin
Spinal cord
Thalamus
Ventricles
VSCC

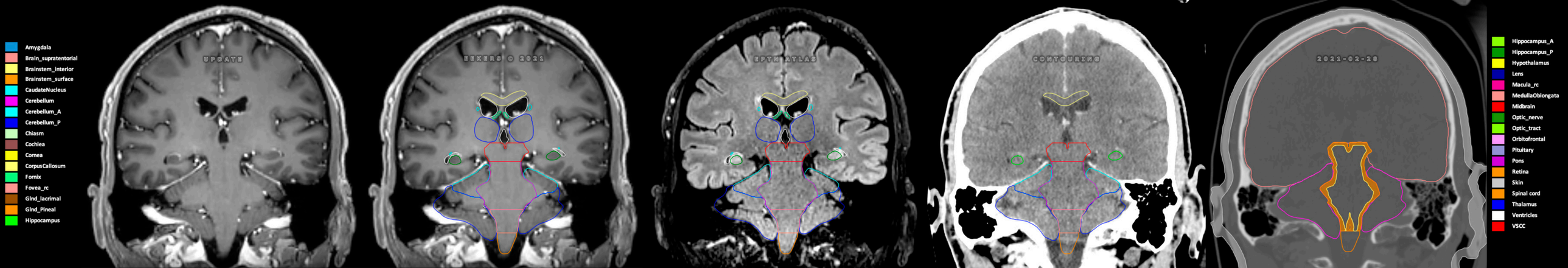
Amygdala
Brain_supratentorial
Brainstem_interior
Brainstem_surface
CaudateNucleus
Cerebellum
Cerebellum_A
Cerebellum_P
Chiasm
Cochlea
Cornea
CorpusCallosum
Fornix
Fovea_rc
Glnd_lacrimal
Glnd_Pineal
Hippocampus
UPDATE
EEKERS © 2021
EPTH ATLAS
CONTOURING
2021-02-28
Hippocampus_A
Hippocampus_P
Hypothalamus
Lens
Macula_rc
MedullaOblongata
Midbrain
Optic_nerve
Optic_tract
Orbitofrontal
Pituitary
Pons
Retina
Skin
Spinal cord
Thalamus
Ventricles
VSCC

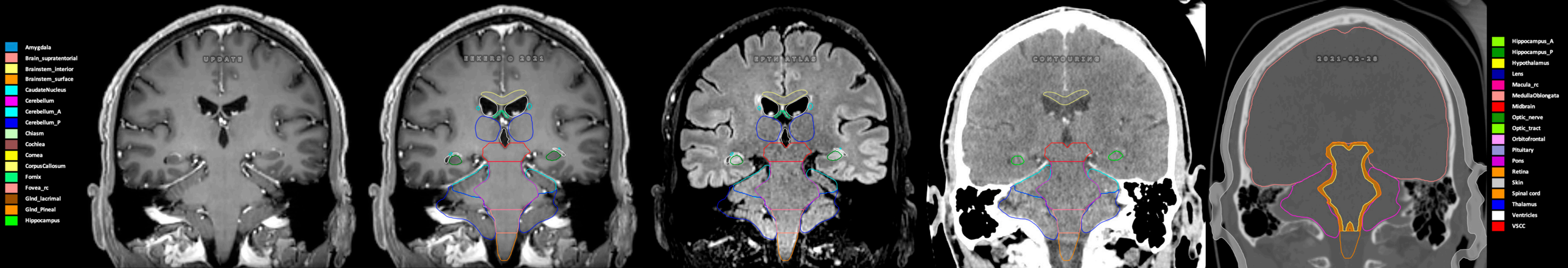
Amygdala
Brain_supratentorial
Brainstem_interior
Brainstem_surface
CaudateNucleus
Cerebellum
Cerebellum_A
Cerebellum_P
Chiasm
Cochlea
Cornea
CorpusCallosum
Fornix
Fovea_rc
Glnd_lacrimal
Glnd_Pineal
Hippocampus
UPDATE
EEKERS © 2021
EPTH ATLAS
CONTOURING
2021-02-28
Hippocampus_A
Hippocampus_P
Hypothalamus
Lens
Macula_rc
MedullaOblongata
Midbrain
Optic_nerve
Optic_tract
Orbitofrontal
Pituitary
Pons
Retina
Skin
Spinal cord
Thalamus
Ventricles
VSCC

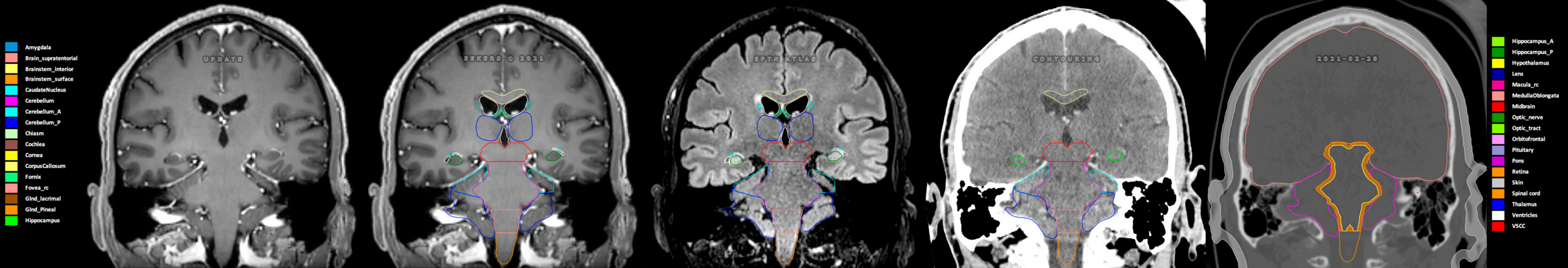
Amygdala
Brain_supratentorial
Brainstem_interior
Brainstem_surface
CaudateNucleus
Cerebellum
Cerebellum_A
Cerebellum_P
Chiasm
Cochlea
Cornea
CorpusCallosum
Fornix
Fovea_rc
Glnd_lacrimal
Glnd_Pineal
Hippocampus
UPDATE
EEKERS © 2021
EPTN ATLAS
CONTOURING
2021-02-28
Hippocampus_A
Hippocampus_P
Hypothalamus
Lens
Macula_rc
MedullaOblongata
Midbrain
Optic_nerve
Optic_tract
Orbitofrontal
Pituitary
Pons
Retina
Skin
Spinal cord
Thalamus
Ventricles
VSCC

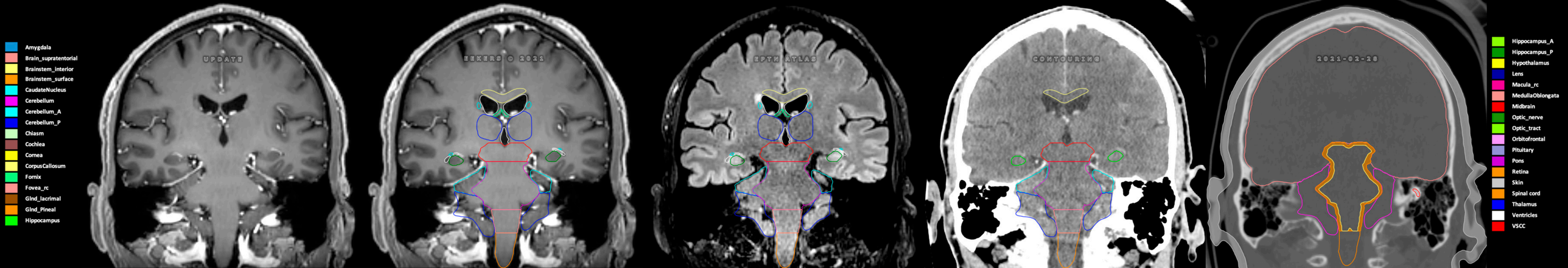
Amygdala
Brain_supratentorial
Brainstem_interior
Brainstem_surface
CaudateNucleus
Cerebellum
Cerebellum_A
Cerebellum_P
Chiasm
Cochlea
Cornea
CorpusCallosum
Fornix
Fovea_rc
Glnd_lacrimal
Glnd_Pineal
Hippocampus
UPDATE
EEKERS © 2021
EPTN ATLAS
CONTOURING
2021-02-28
Hippocampus_A
Hippocampus_P
Hypothalamus
Lens
Macula_rc
MedullaOblongata
Midbrain
Optic_nerve
Optic_tract
Orbitofrontal
Pituitary
Pons
Retina
Skin
Spinal cord
Thalamus
Ventricles
VSCC

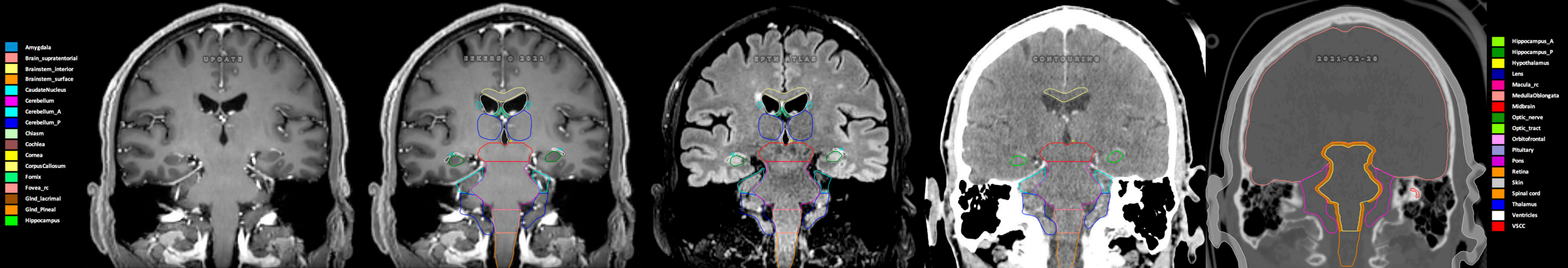
Amygdala
Brain_supratentorial
Brainstem_interior
Brainstem_surface
CaudateNucleus
Cerebellum
Cerebellum_A
Cerebellum_P
Chiasm
Cochlea
Cornea
CorpusCallosum
Fornix
Fovea_rc
Glnd_lacrimal
Glnd_Pineal
Hippocampus
UPDATE
EKERS © 2021
EPTN ATLAS
CONTOURING
2021-02-28
Hippocampus_A
Hippocampus_P
Hypothalamus
Lens
Macula_rc
MedullaOblongata
Midbrain
Optic_nerve
Optic_tract
Orbitofrontal
Pituitary
Pons
Retina
Skin
Spinal cord
Thalamus
Ventricles
VSCC

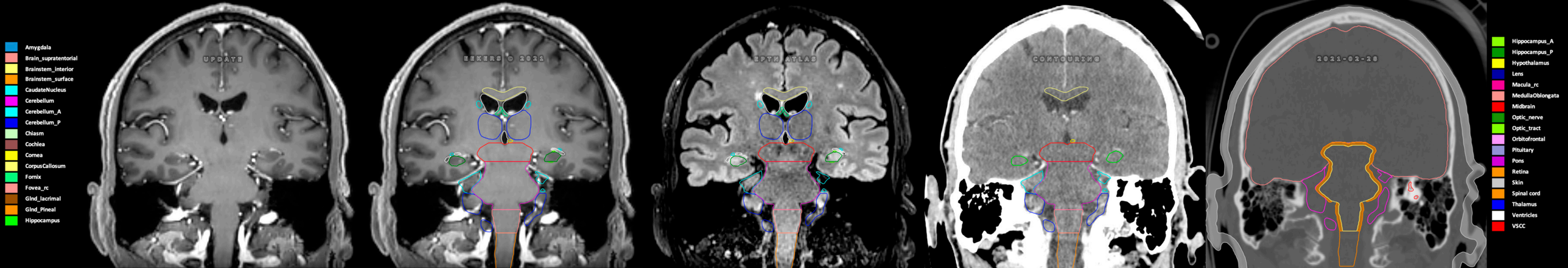
Amygdala
Brain_supratentorial
Brainstem_interior
Brainstem_surface
CaudateNucleus
Cerebellum
Cerebellum_A
Cerebellum_P
Chiasm
Cochlea
Cornea
CorpusCallosum
Fornix
Fovea_rc
Glnd_lacrimal
Glnd_Pineal
Hippocampus
UPDATE
EKERS © 2021
EPTN ATLAS
CONTOURING
2021-02-28
Hippocampus_A
Hippocampus_P
Hypothalamus
Lens
Macula_rc
MedullaOblongata
Midbrain
Optic_nerve
Optic_tract
Orbitofrontal
Pituitary
Pons
Retina
Skin
Spinal cord
Thalamus
Ventricles
VSCC

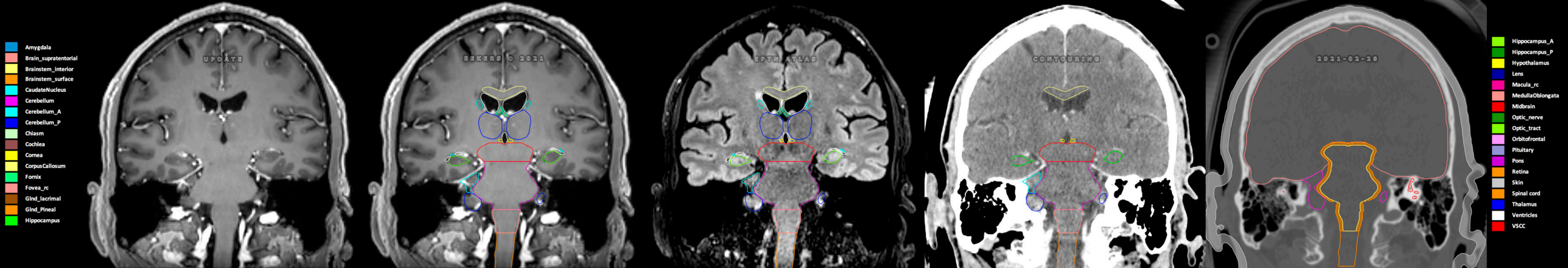
Amygdala
Brain_supratentorial
Brainstem_interior
Brainstem_surface
CaudateNucleus
Cerebellum
Cerebellum_A
Cerebellum_P
Chiasm
Cochlea
Cornea
CorpusCallosum
Fornix
Fovea_rc
Glnd_lacrimal
Glnd_Pineal
Hippocampus
UPDATE
EIKERS © 2021
EPTN ATLAS
CONTOURING
2021-02-28
Hippocampus_A
Hippocampus_P
Hypothalamus
Lens
Macula_rc
MedullaOblongata
Midbrain
Optic_nerve
Optic_tract
Orbitofrontal
Pituitary
Pons
Retina
Skin
Spinal cord
Thalamus
Ventricles
VSCC

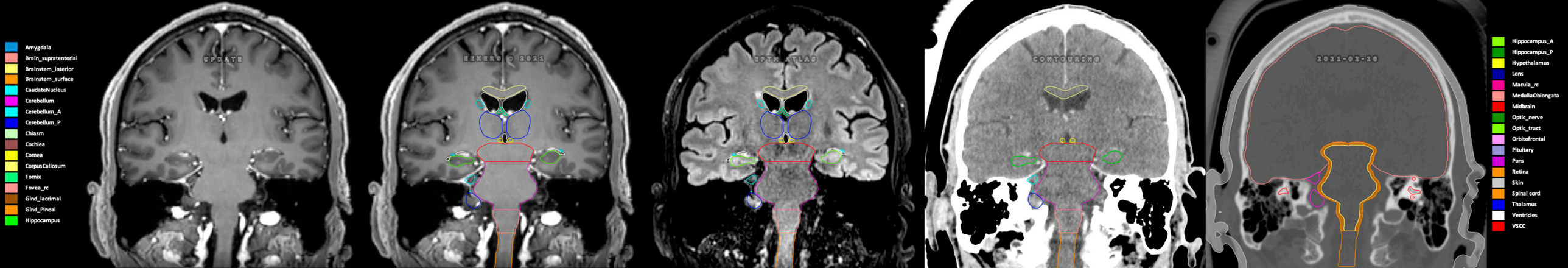
Amygdala
Brain_supratentorial
Brainstem_interior
Brainstem_surface
CaudateNucleus
Cerebellum
Cerebellum_A
Cerebellum_P
Chiasm
Cochlea
Cornea
CorpusCallosum
Fornix
Fovea_rc
Glnd_lacrimal
Glnd_Pineal
Hippocampus
UPDATE
EEKERS © 2021
EPTN ATLAS
CONTOURING
2021-02-28
Hippocampus_A
Hippocampus_P
Hypothalamus
Lens
Macula_rc
MedullaOblongata
Midbrain
Optic_nerve
Optic_tract
Orbitofrontal
Pituitary
Pons
Retina
Skin
Spinal cord
Thalamus
Ventricles
VSCC

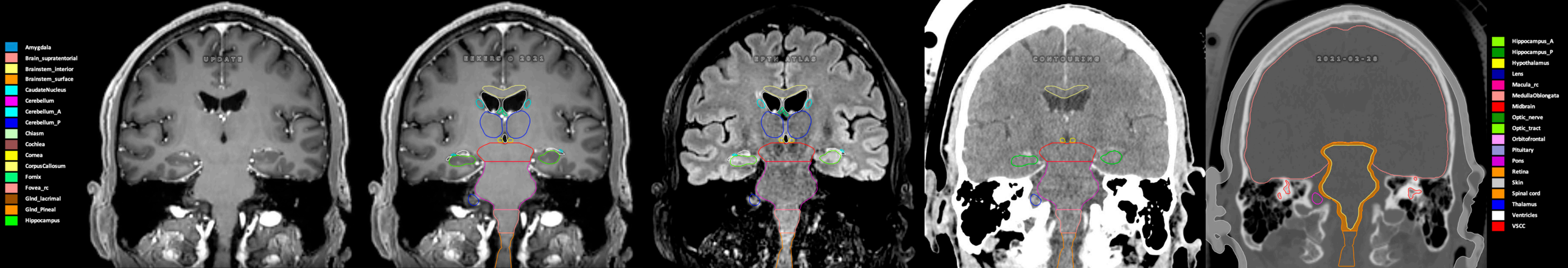
Amygdala
Brain_supratentorial
Brainstem_interior
Brainstem_surface
CaudateNucleus
Cerebellum
Cerebellum_A
Cerebellum_P
Chiasm
Cochlea
Cornea
CorpusCallosum
Fornix
Fovea_rc
Glnd_lacrimal
Glnd_Pineal
Hippocampus
UPDATE
EKENS © 2021
EPTN ATLAS
CONTOURING
2021-02-28
Hippocampus_A
Hippocampus_P
Hypothalamus
Lens
Macula_rc
MedullaOblongata
Midbrain
Optic_nerve
Optic_tract
Orbitofrontal
Pituitary
Pons
Retina
Skin
Spinal cord
Thalamus
Ventricles
VSCC

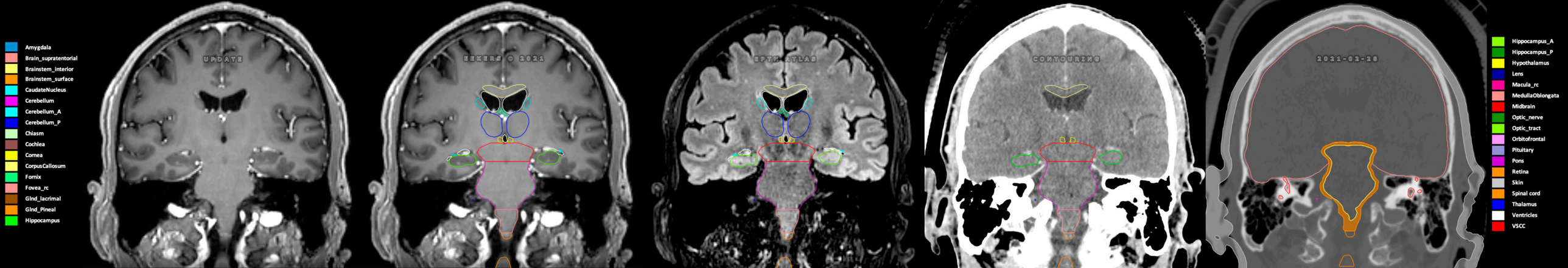
Amygdala
Brain_supratentorial
Brainstem_interior
Brainstem_surface
CaudateNucleus
Cerebellum
Cerebellum_A
Cerebellum_P
Chiasm
Cochlea
Cornea
CorpusCallosum
Fornix
Fovea_rc
Glnd_lacrimal
Glnd_Pineal
Hippocampus
UPDATE
EIKERS © 2021
EPTN ATLAS
CONTOURING
2021-02-28
Hippocampus_A
Hippocampus_P
Hypothalamus
Lens
Macula_rc
MedullaOblongata
Midbrain
Optic_nerve
Optic_tract
Orbitofrontal
Pituitary
Pons
Retina
Skin
Spinal cord
Thalamus
Ventricles
VSCC

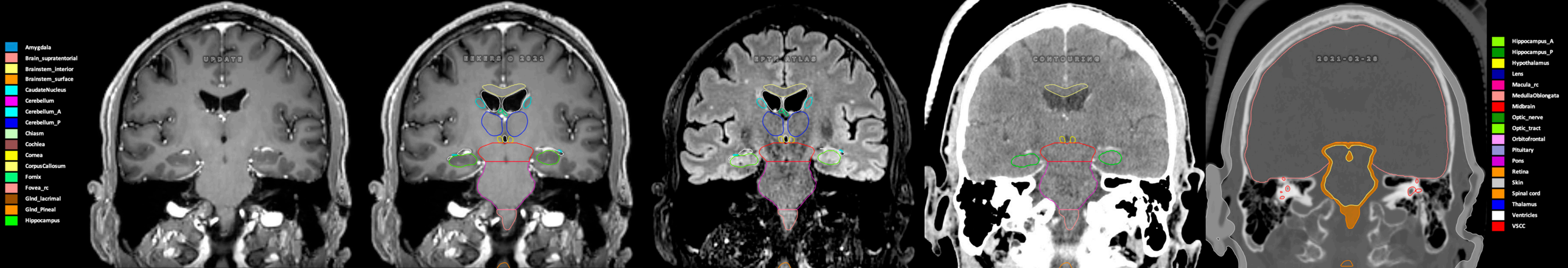
Amygdala
Brain_supratentorial
Brainstem_interior
Brainstem_surface
CaudateNucleus
Cerebellum
Cerebellum_A
Cerebellum_P
Chiasm
Cochlea
Cornea
CorpusCallosum
Fornix
Fovea_rc
Glnd_lacrimal
Glnd_Pineal
Hippocampus
UPDATE
EKERS © 2021
EPTH ATLAS
CONTOURING
2021-02-28
Hippocampus_A
Hippocampus_P
Hypothalamus
Lens
Macula_rc
MedullaOblongata
Midbrain
Optic_nerve
Optic_tract
Orbitofrontal
Pituitary
Pons
Retina
Skin
Spinal cord
Thalamus
Ventricles
VSCC

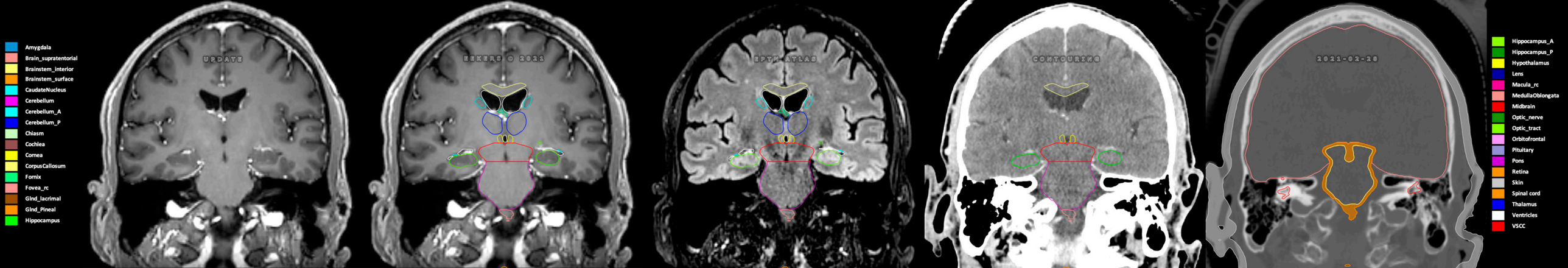
Amygdala
Brain_supratentorial
Brainstem_interior
Brainstem_surface
CaudateNucleus
Cerebellum
Cerebellum_A
Cerebellum_P
Chiasm
Cochlea
Cornea
CorpusCallosum
Fornix
Fovea_rc
Glnd_lacrimal
Glnd_Pineal
Hippocampus
UPDATE
EEKERS © 2021
UPTM ATLAS
CONTOURING
2021-02-28
Hippocampus_A
Hippocampus_P
Hypothalamus
Lens
Macula_rc
MedullaOblongata
Midbrain
Optic_nerve
Optic_tract
Orbitofrontal
Pituitary
Pons
Retina
Skin
Spinal cord
Thalamus
Ventricles
VSCC

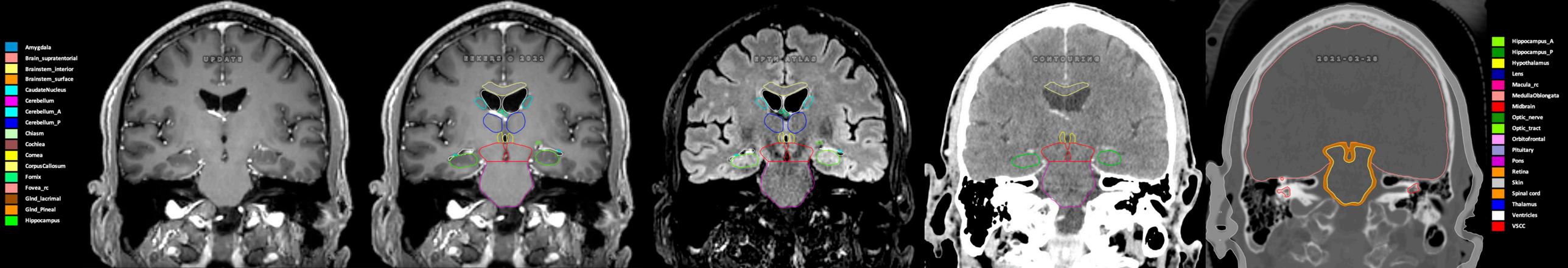
Amygdala
Brain_supratentorial
Brainstem_interior
Brainstem_surface
CaudateNucleus
Cerebellum
Cerebellum_A
Cerebellum_P
Chiasm
Cochlea
Cornea
CorpusCallosum
Fornix
Fovea_rc
Glnd_lacrimal
Glnd_Pineal
Hippocampus
UPDATE
EKERS © 2021
EPTH ATLAS
CONTOURING
2021-02-28
Hippocampus_A
Hippocampus_P
Hypothalamus
Lens
Macula_rc
MedullaOblongata
Midbrain
Optic_nerve
Optic_tract
Orbitofrontal
Pituitary
Pons
Retina
Skin
Spinal cord
Thalamus
Ventricles
VSCC

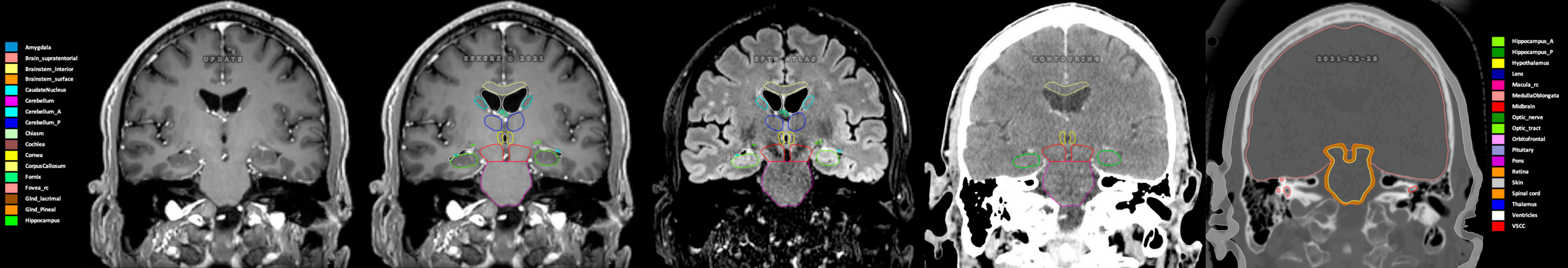
Amygdala
Brain_supratentorial
Brainstem_interior
Brainstem_surface
CaudateNucleus
Cerebellum
Cerebellum_A
Cerebellum_P
Chiasm
Cochlea
Cornea
CorpusCallosum
Fornix
Fovea_rc
Glnd_lacrimal
Glnd_Pineal
Hippocampus
UPDATE
EKERS © 2021
EPTH ATLAS
CONTOURING
2021-02-28
Hippocampus_A
Hippocampus_P
Hypothalamus
Lens
Macula_rc
MedullaOblongata
Midbrain
Optic_nerve
Optic_tract
Orbitofrontal
Pituitary
Pons
Retina
Skin
Spinal cord
Thalamus
Ventricles
VSCC

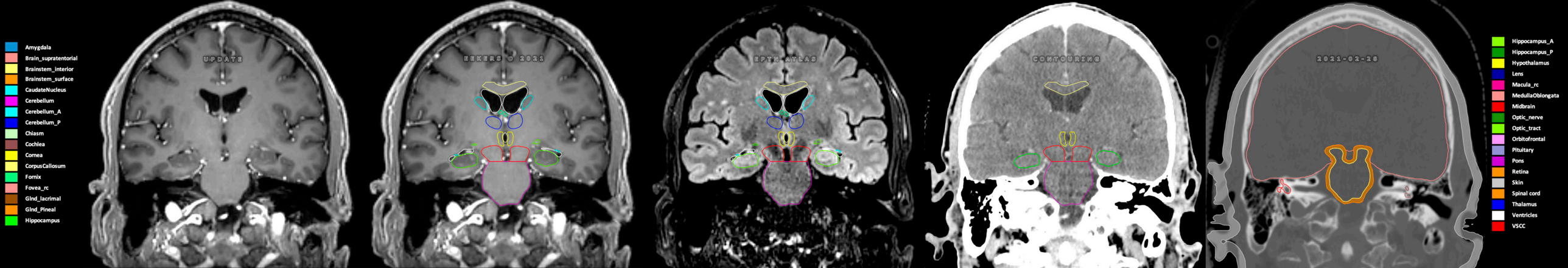
Amygdala
Brain_supratentorial
Brainstem_interior
Brainstem_surface
CaudateNucleus
Cerebellum
Cerebellum_A
Cerebellum_P
Chiasm
Cochlea
Cornea
CorpusCallosum
Fornix
Fovea_rc
Glnd_lacrimal
Glnd_Pineal
Hippocampus
UPDATE
EEKERS © 2021
EPTN ATLAS
CONTOURING
2021-02-28
Hippocampus_A
Hippocampus_P
Hypothalamus
Lens
Macula_rc
MedullaOblongata
Midbrain
Optic_nerve
Optic_tract
Orbitofrontal
Pituitary
Pons
Retina
Skin
Spinal cord
Thalamus
Ventricles
VSCC

Amygdala
Brain_supratentorial
Brainstem_interior
Brainstem_surface
CaudateNucleus
Cerebellum
Cerebellum_A
Cerebellum_P
Chiasm
Cochlea
Cornea
CorpusCallosum
Fornix
Fovea_rc
Glnd_lacrimal
Glnd_Pineal
Hippocampus
UPDATE
EKERS © 2021
EPTN ATLAS
CONTOURING
2021-02-28
Hippocampus_A
Hippocampus_P
Hypothalamus
Lens
Macula_rc
MedullaOblongata
Midbrain
Optic_nerve
Optic_tract
Orbitofrontal
Pituitary
Pons
Retina
Skin
Spinal cord
Thalamus
Ventricles
VSCC

Amygdala
Brain_supratentorial
Brainstem_interior
Brainstem_surface
CaudateNucleus
Cerebellum
Cerebellum_A
Cerebellum_P
Chiasm
Cochlea
Cornea
CorpusCallosum
Fornix
Fovea_rc
Glnd_lacrimal
Glnd_Pineal
Hippocampus
UPDATE
EKEKES 0 2021
EPTH ATLAS
CONTOURING
2021-02-28
Hippocampus_A
Hippocampus_P
Hypothalamus
Lens
Macula_rc
MedullaOblongata
Midbrain
Optic_nerve
Optic_tract
Orbitofrontal
Pituitary
Pons
Retina
Skin
Spinal cord
Thalamus
Ventricles
VSCC

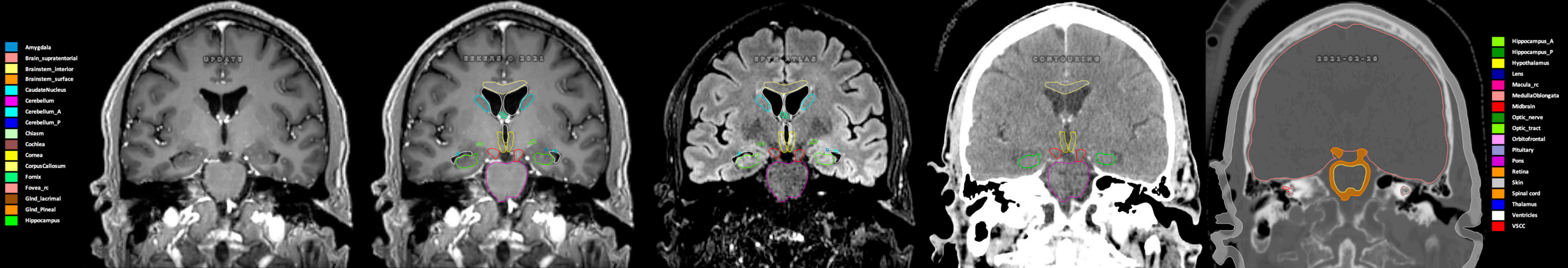
Amygdala
Brain_supratentorial
Brainstem_interior
Brainstem_surface
CaudateNucleus
Cerebellum
Cerebellum_A
Cerebellum_P
Chiasm
Cochlea
Cornea
CorpusCallosum
Fornix
Fovea_rc
Glnd_lacrimal
Glnd_Pineal
Hippocampus
UPDATE
EKENS © 2021
EPTN ATLAS
CONTOURING
2021-02-28
Hippocampus_A
Hippocampus_P
Hypothalamus
Lens
Macula_rc
MedullaOblongata
Midbrain
Optic_nerve
Optic_tract
Orbitofrontal
Pituitary
Pons
Retina
Skin
Spinal cord
Thalamus
Ventricles
VSCC

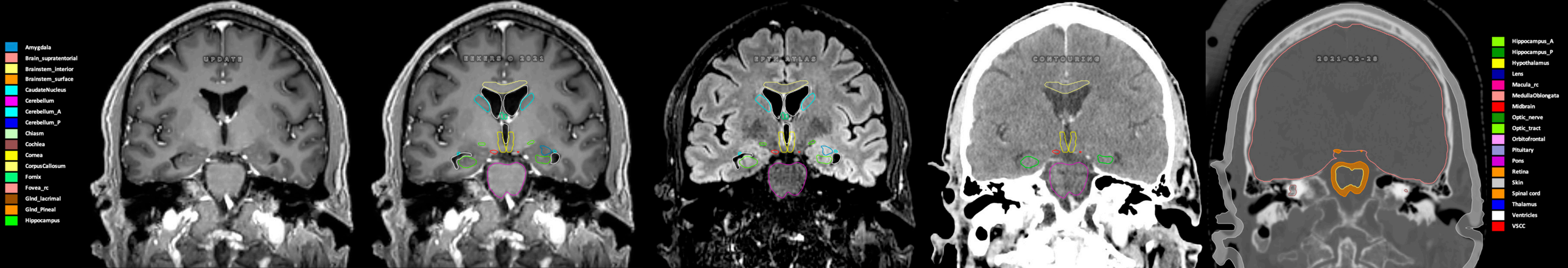
Amygdala
Brain_supratentorial
Brainstem_interior
Brainstem_surface
CaudateNucleus
Cerebellum
Cerebellum_A
Cerebellum_P
Chiasm
Cochlea
Cornea
CorpusCallosum
Fornix
Fovea_rc
Glnd_lacrimal
Glnd_Pineal
Hippocampus
UPDATE
EKEKS © 2021
EPTN ATLAS
CONTOURING
2021-02-28
Hippocampus_A
Hippocampus_P
Hypothalamus
Lens
Macula_rc
MedullaOblongata
Midbrain
Optic_nerve
Optic_tract
Orbitofrontal
Pituitary
Pons
Retina
Skin
Spinal cord
Thalamus
Ventricles
VSCC

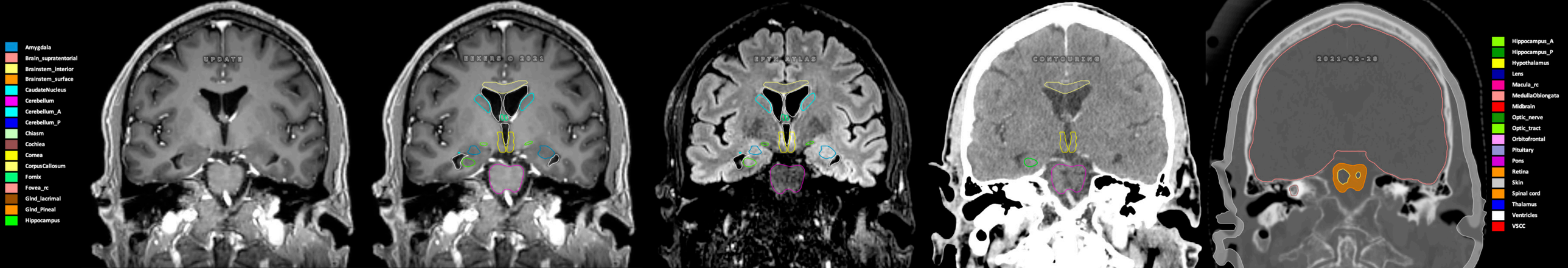
Amygdala
Brain_supratentorial
Brainstem_interior
Brainstem_surface
CaudateNucleus
Cerebellum
Cerebellum_A
Cerebellum_P
Chiasm
Cochlea
Cornea
CorpusCallosum
Fornix
Fovea_rc
Glnd_lacrimal
Glnd_Pineal
Hippocampus
UPDATE
EKERS © 2021
EPTH ATLAS
CONTOURING
2021-02-28
Hippocampus_A
Hippocampus_P
Hypothalamus
Lens
Macula_rc
MedullaOblongata
Midbrain
Optic_nerve
Optic_tract
Orbitofrontal
Pituitary
Pons
Retina
Skin
Spinal cord
Thalamus
Ventricles
VSCC

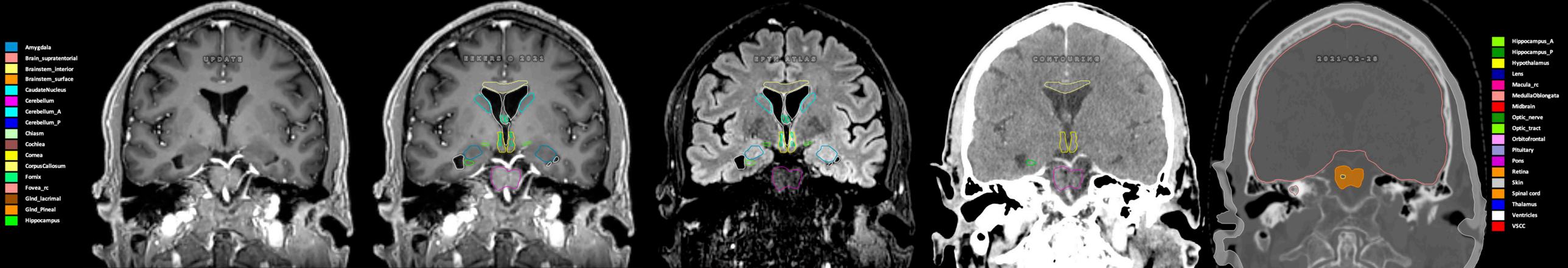
Amygdala
Brain_supratentorial
Brainstem_interior
Brainstem_surface
CaudateNucleus
Cerebellum
Cerebellum_A
Cerebellum_P
Chiasm
Cochlea
Cornea
CorpusCallosum
Fornix
Fovea_rc
Glnd_lacrimal
Glnd_Pineal
Hippocampus
UPDATE
EKERS © 2021
EPTH ATLAS
CONTOURING
2021-02-28
Hippocampus_A
Hippocampus_P
Hypothalamus
Lens
Macula_rc
MedullaOblongata
Midbrain
Optic_nerve
Optic_tract
Orbitofrontal
Pituitary
Pons
Retina
Skin
Spinal cord
Thalamus
Ventricles
VSCC

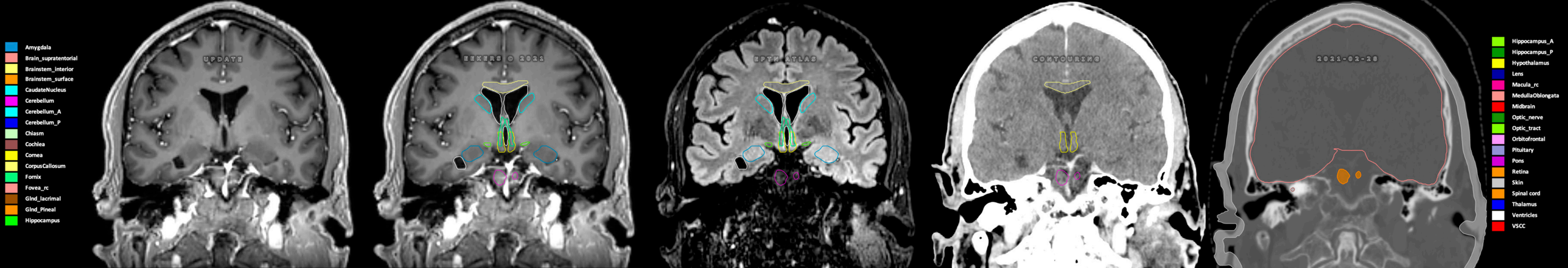
Amygdala
Brain_supratentorial
Brainstem_interior
Brainstem_surface
CaudateNucleus
Cerebellum
Cerebellum_A
Cerebellum_P
Chiasm
Cochlea
Cornea
CorpusCallosum
Fornix
Fovea_rc
Glnd_lacrimal
Glnd_Pineal
Hippocampus
UPDATE
EKERS © 2021
UPTM ATLAS
CONTOURING
2021-02-28
Hippocampus_A
Hippocampus_P
Hypothalamus
Lens
Macula_rc
MedullaOblongata
Midbrain
Optic_nerve
Optic_tract
Orbitofrontal
Pituitary
Pons
Retina
Skin
Spinal cord
Thalamus
Ventricles
VSCC

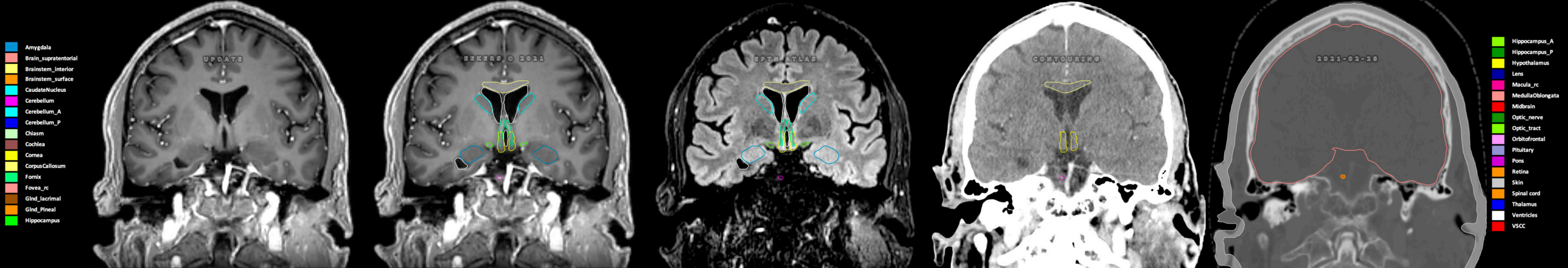
Amygdala
Brain_supratentorial
Brainstem_interior
Brainstem_surface
CaudateNucleus
Cerebellum
Cerebellum_A
Cerebellum_P
Chiasm
Cochlea
Cornea
CorpusCallosum
Fornix
Fovea_rc
Glnd_lacrimal
Glnd_Pineal
Hippocampus
UPDATE
EIKERS © 2021
EPTN ATLAS
CONTOURING
2021-02-28
Hippocampus_A
Hippocampus_P
Hypothalamus
Lens
Macula_rc
MedullaOblongata
Midbrain
Optic_nerve
Optic_tract
Orbitofrontal
Pituitary
Pons
Retina
Skin
Spinal cord
Thalamus
Ventricles
VSCC

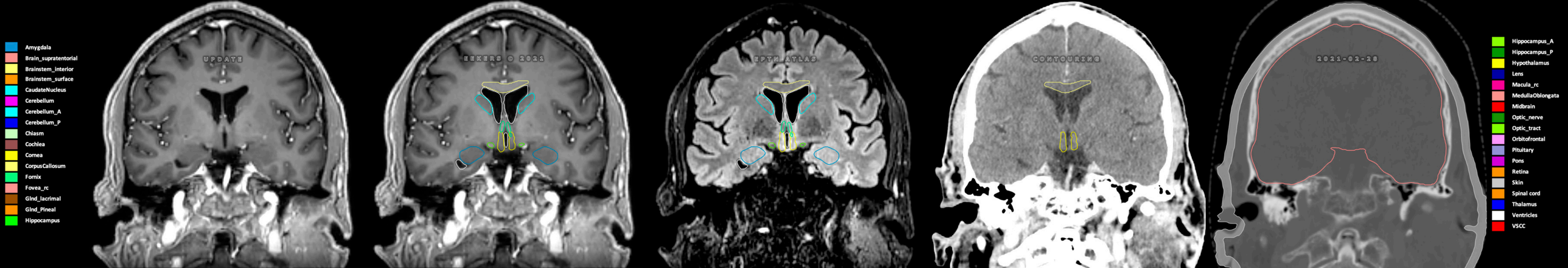
Amygdala
Brain_supratentorial
Brainstem_interior
Brainstem_surface
CaudateNucleus
Cerebellum
Cerebellum_A
Cerebellum_P
Chiasm
Cochlea
Cornea
CorpusCallosum
Fornix
Fovea_rc
Gland_lacrimal
Gland_Pineal
Hippocampus
UPDATE
EKERS © 2021
EPTH ATLAS
CONTOURING
2021-02-28
Hippocampus_A
Hippocampus_P
Hypothalamus
Lens
Macula_rc
MedullaOblongata
Midbrain
Optic_nerve
Optic_tract
Orbitofrontal
Pituitary
Pons
Retina
Skin
Spinal cord
Thalamus
Ventricles
VSCC

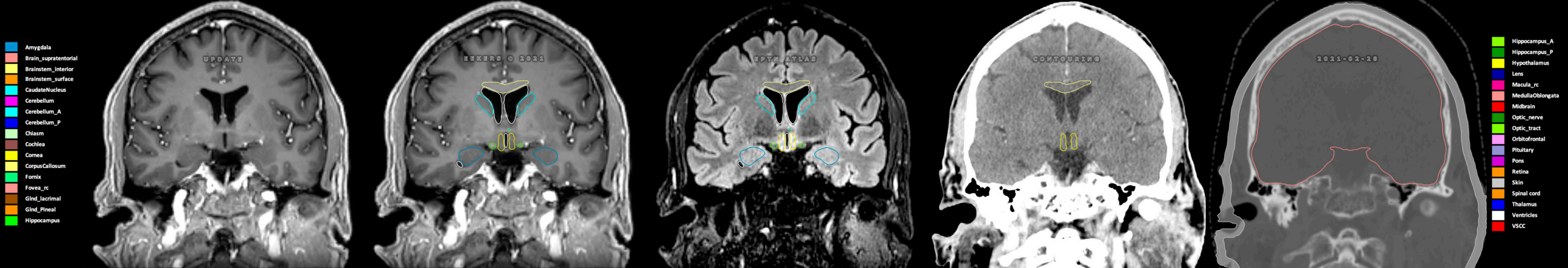
Amygdala
Brain_supratentorial
Brainstem_interior
Brainstem_surface
CaudateNucleus
Cerebellum
Cerebellum_A
Cerebellum_P
Chiasm
Cochlea
Cornea
CorpusCallosum
Fornix
Fovea_rc
Glnd_lacrimal
Glnd_Pineal
Hippocampus
UPDATE
EKERS © 2021
EPTN ATLAS
CONTOURING
2021-02-28
Hippocampus_A
Hippocampus_P
Hypothalamus
Lens
Macula_rc
MedullaOblongata
Midbrain
Optic_nerve
Optic_tract
Orbitofrontal
Pituitary
Pons
Retina
Skin
Spinal cord
Thalamus
Ventricles
VSCC

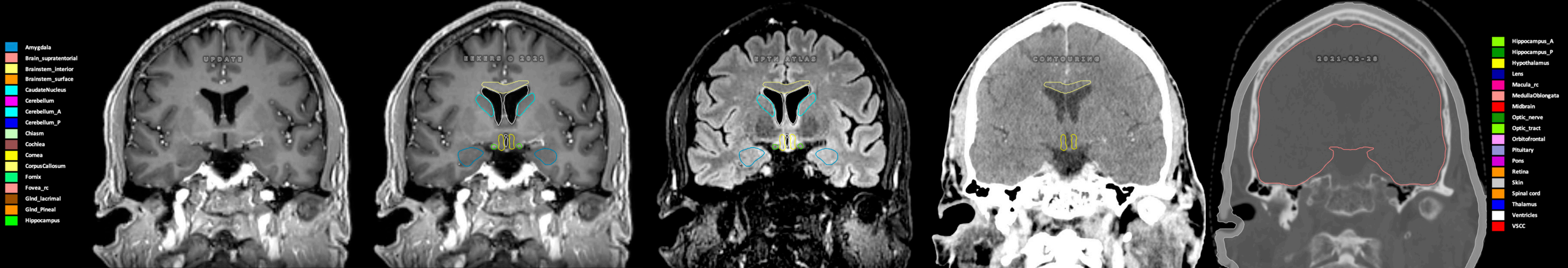
Amygdala
Brain_supratentorial
Brainstem_interior
Brainstem_surface
CaudateNucleus
Cerebellum
Cerebellum_A
Cerebellum_P
Chiasm
Cochlea
Cornea
CorpusCallosum
Fornix
Fovea_rc
Glnd_lacrimal
Glnd_Pineal
Hippocampus
UPDATE
EKERS © 2021
UPTH ATLAS
CONTOURING
2021-02-28
Hippocampus_A
Hippocampus_P
Hypothalamus
Lens
Macula_rc
MedullaOblongata
Midbrain
Optic_nerve
Optic_tract
Orbitofrontal
Pituitary
Pons
Retina
Skin
Spinal cord
Thalamus
Ventricles
VSCC

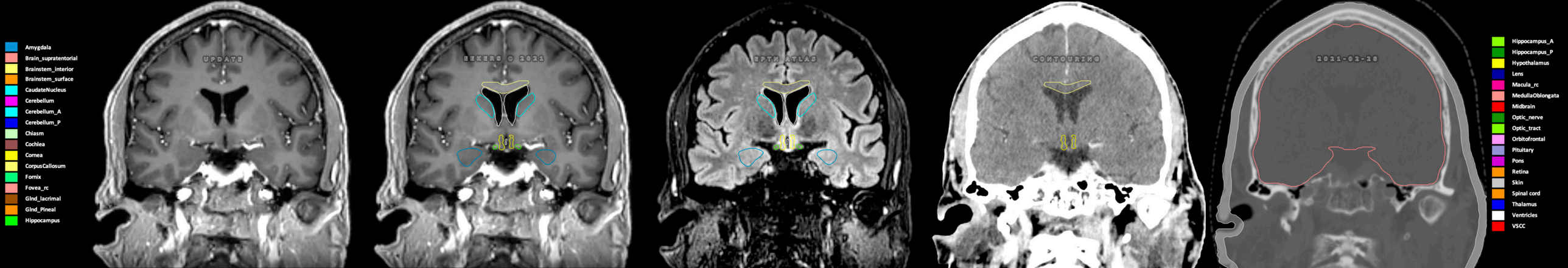
Amygdala
Brain_supratentorial
Brainstem_interior
Brainstem_surface
CaudateNucleus
Cerebellum
Cerebellum_A
Cerebellum_P
Chiasm
Cochlea
Cornea
CorpusCallosum
Fornix
Fovea_rc
Glnd_lacrimal
Glnd_Pineal
Hippocampus
UPDATE
EEKERS © 2021
UPTH ATLAS
CONTOURING
2021-02-28
Hippocampus_A
Hippocampus_P
Hypothalamus
Lens
Macula_rc
MedullaOblongata
Midbrain
Optic_nerve
Optic_tract
Orbitofrontal
Pituitary
Pons
Retina
Skin
Spinal cord
Thalamus
Ventricles
VSCC

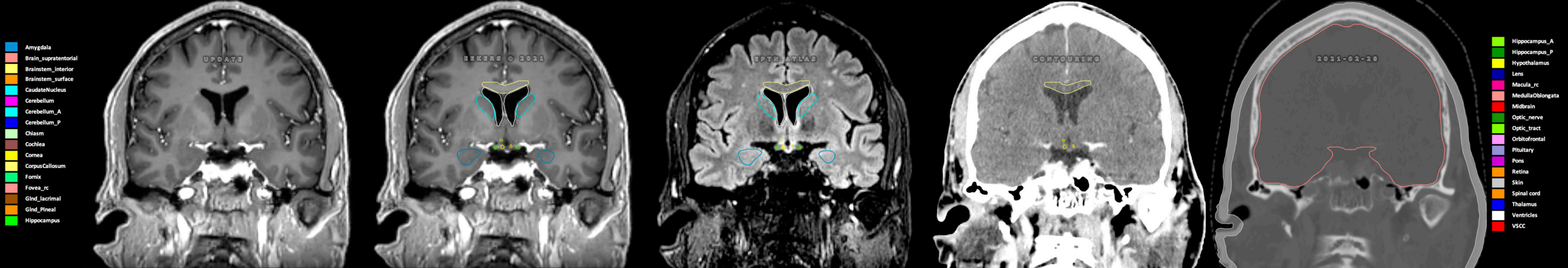
Amygdala
Brain_supratentorial
Brainstem_interior
Brainstem_surface
CaudateNucleus
Cerebellum
Cerebellum_A
Cerebellum_P
Chiasm
Cochlea
Cornea
CorpusCallosum
Fornix
Fovea_rc
Glnd_lacrimal
Glnd_Pineal
Hippocampus
UPDATE
EKERS © 2021
UPTH ATLAS
CONTOURING
2021-02-28
Hippocampus_A
Hippocampus_P
Hypothalamus
Lens
Macula_rc
MedullaOblongata
Midbrain
Optic_nerve
Optic_tract
Orbitofrontal
Pituitary
Pons
Retina
Skin
Spinal cord
Thalamus
Ventricles
VSCC

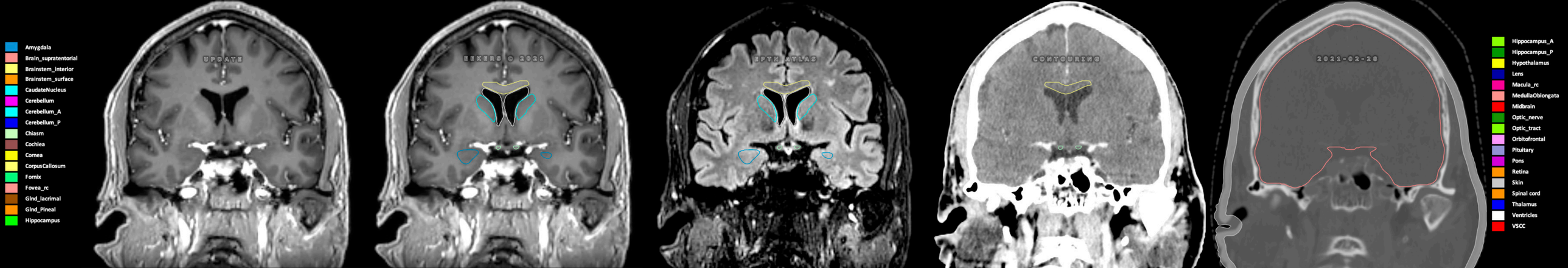
Amygdala
Brain_supratentorial
Brainstem_interior
Brainstem_surface
CaudateNucleus
Cerebellum
Cerebellum_A
Cerebellum_P
Chiasm
Cochlea
Cornea
CorpusCallosum
Fornix
Fovea_rc
Glnd_lacrimal
Glnd_Pineal
Hippocampus
UPDATE
EEKERS © 2021
EPTH ATLAS
CONTOURING
2021-02-28
Hippocampus_A
Hippocampus_P
Hypothalamus
Lens
Macula_rc
MedullaOblongata
Midbrain
Optic_nerve
Optic_tract
Orbitofrontal
Pituitary
Pons
Retina
Skin
Spinal cord
Thalamus
Ventricles
VSCC

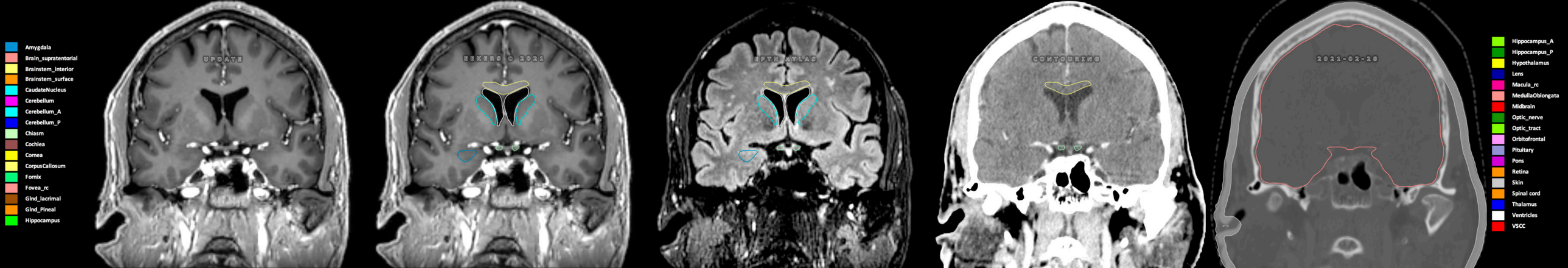
Amygdala
Brain_supratentorial
Brainstem_interior
Brainstem_surface
CaudateNucleus
Cerebellum
Cerebellum_A
Cerebellum_P
Chiasm
Cochlea
Cornea
CorpusCallosum
Fornix
Fovea_rc
Gland_lacrimal
Gland_Pineal
Hippocampus
UPDATE
EKERS © 2021
EPTN ATLAS
CONTOURING
2021-02-28
Hippocampus_A
Hippocampus_P
Hypothalamus
Lens
Macula_rc
MedullaOblongata
Midbrain
Optic_nerve
Optic_tract
Orbitofrontal
Pituitary
Pons
Retina
Skin
Spinal cord
Thalamus
Ventricles
VSCC

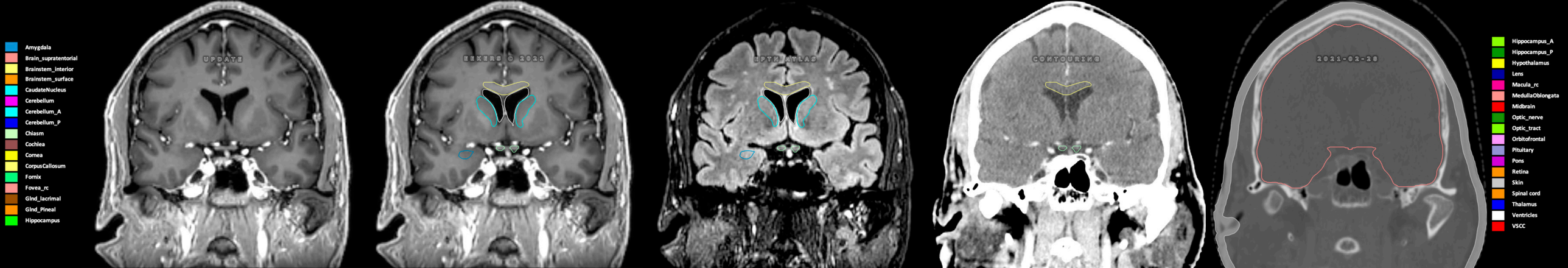
Amygdala
Brain_supratentorial
Brainstem_interior
Brainstem_surface
CaudateNucleus
Cerebellum
Cerebellum_A
Cerebellum_P
Chiasm
Cochlea
Cornea
CorpusCallosum
Fornix
Fovea_rc
Glnd_lacrimal
Glnd_Pineal
Hippocampus
UPDATE
EEKERS © 2021
UPTH ATLAS
CONTOURING
2021-02-28
Hippocampus_A
Hippocampus_P
Hypothalamus
Lens
Macula_rc
MedullaOblongata
Midbrain
Optic_nerve
Optic_tract
Orbitofrontal
Pituitary
Pons
Retina
Skin
Spinal cord
Thalamus
Ventricles
VSCC

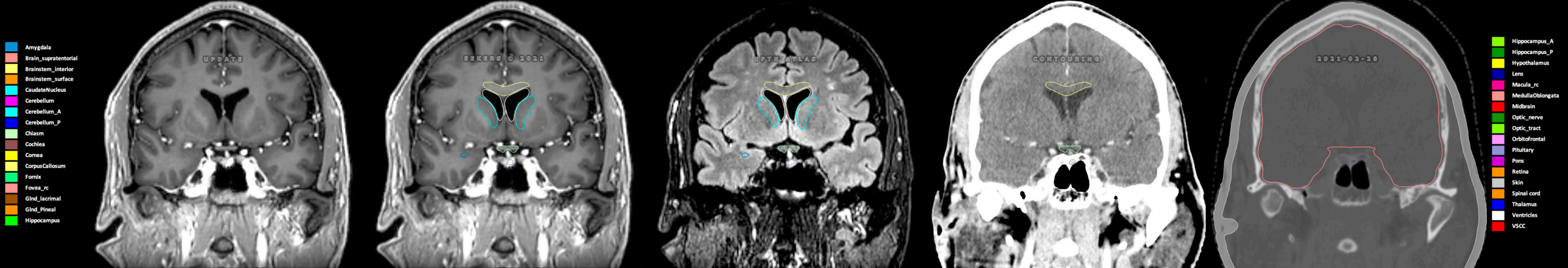
Amygdala
Brain_supratentorial
Brainstem_interior
Brainstem_surface
CaudateNucleus
Cerebellum
Cerebellum_A
Cerebellum_P
Chiasm
Cochlea
Cornea
CorpusCallosum
Fornix
Fovea_rc
Glnd_lacrimal
Glnd_Pineal
Hippocampus
UPDATE
EKERS © 2021
UPTH ATLAS
CONTOURING
2021-02-28
Hippocampus_A
Hippocampus_P
Hypothalamus
Lens
Macula_rc
MedullaOblongata
Midbrain
Optic_nerve
Optic_tract
Orbitofrontal
Pituitary
Pons
Retina
Skin
Spinal cord
Thalamus
Ventricles
VSCC

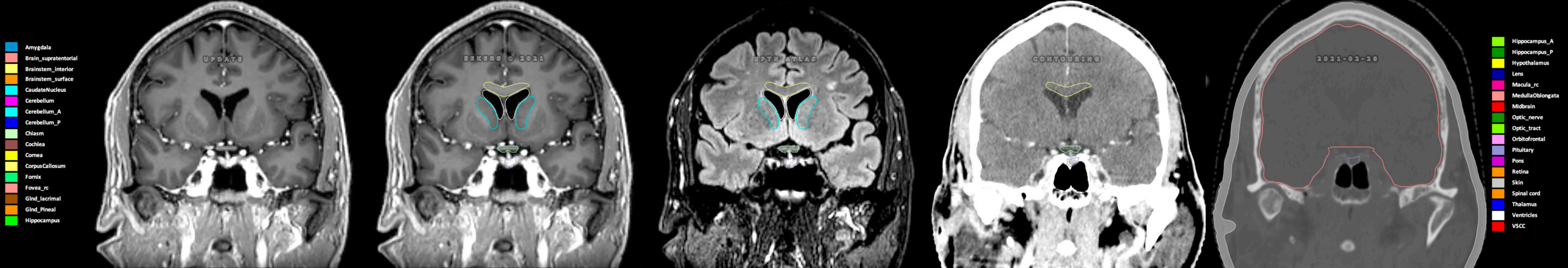
Amygdala
Brain_supratentorial
Brainstem_interior
Brainstem_surface
CaudateNucleus
Cerebellum
Cerebellum_A
Cerebellum_P
Chiasm
Cochlea
Cornea
CorpusCallosum
Fornix
Fovea_rc
Gland_lacrimal
Gland_Pineal
Hippocampus
UPDATE
EKERS © 2021
EPTN ATLAS
CONTOURING
2021-02-28
Hippocampus_A
Hippocampus_P
Hypothalamus
Lens
Macula_rc
MedullaOblongata
Midbrain
Optic_nerve
Optic_tract
Orbitofrontal
Pituitary
Pons
Retina
Skin
Spinal cord
Thalamus
Ventricles
VSCC

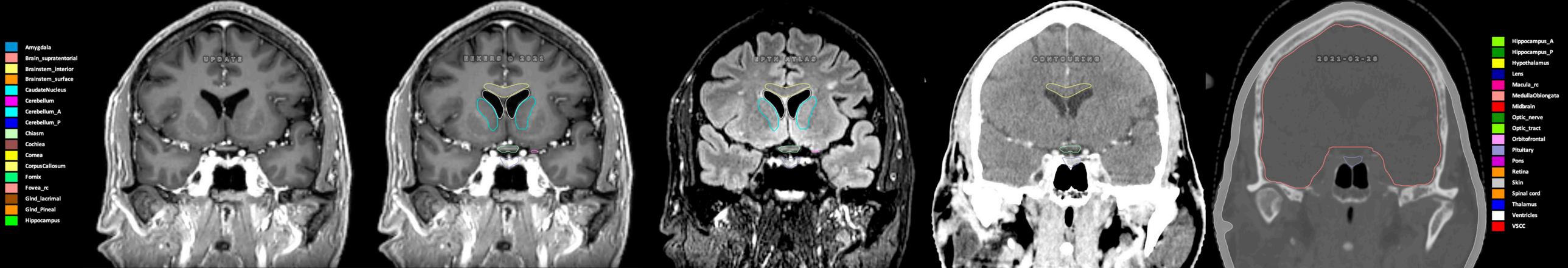
Amygdala
Brain_supratentorial
Brainstem_interior
Brainstem_surface
CaudateNucleus
Cerebellum
Cerebellum_A
Cerebellum_P
Chiasm
Cochlea
Cornea
CorpusCallosum
Fornix
Fovea_rc
Glnd_lacrimal
Glnd_Pineal
Hippocampus
UPDATE
EKERS © 2021
EPTH ATLAS
CONTOURING
2021-02-28
Hippocampus_A
Hippocampus_P
Hypothalamus
Lens
Macula_rc
MedullaOblongata
Midbrain
Optic_nerve
Optic_tract
Orbitofrontal
Pituitary
Pons
Retina
Skin
Spinal cord
Thalamus
Ventricles
VSCC

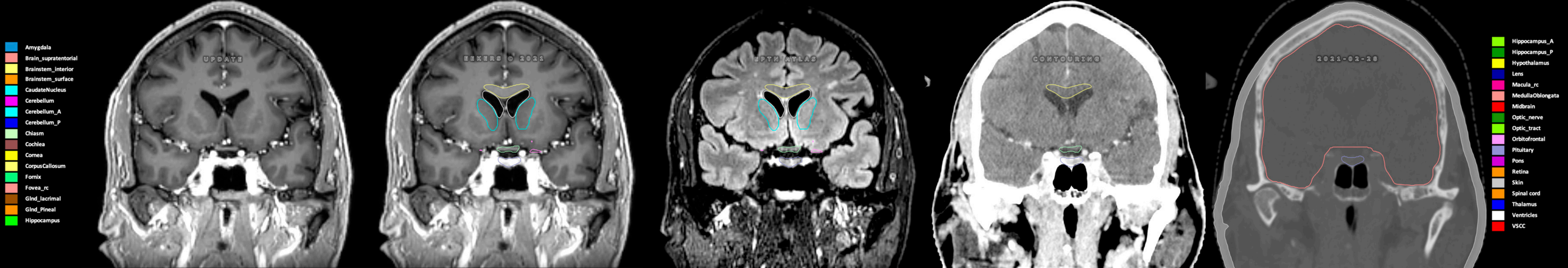
Amygdala
Brain_supratentorial
Brainstem_interior
Brainstem_surface
CaudateNucleus
Cerebellum
Cerebellum_A
Cerebellum_P
Chiasm
Cochlea
Cornea
CorpusCallosum
Fornix
Fovea_rc
Glnd_lacrimal
Glnd_Pineal
Hippocampus
UPDATE
EKERS © 2021
EPTH ATLAS
CONTOURING
2021-02-28
Hippocampus_A
Hippocampus_P
Hypothalamus
Lens
Macula_rc
MedullaOblongata
Midbrain
Optic_nerve
Optic_tract
Orbitofrontal
Pituitary
Pons
Retina
Skin
Spinal cord
Thalamus
Ventricles
VSCC

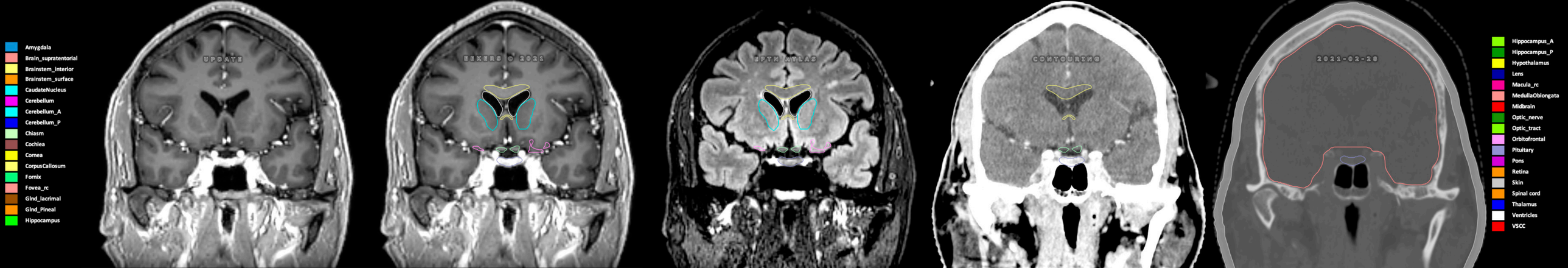
Amygdala
Brain_supratentorial
Brainstem_interior
Brainstem_surface
CaudateNucleus
Cerebellum
Cerebellum_A
Cerebellum_P
Chiasm
Cochlea
Cornea
CorpusCallosum
Fornix
Fovea_rc
Glnd_lacrimal
Glnd_Pineal
Hippocampus
UPDATE
EEKERS © 2021
EPTH ATLAS
CONTOURING
2021-02-28
Hippocampus_A
Hippocampus_P
Hypothalamus
Lens
Macula_rc
MedullaOblongata
Midbrain
Optic_nerve
Optic_tract
Orbitofrontal
Pituitary
Pons
Retina
Skin
Spinal cord
Thalamus
Ventricles
VSCC

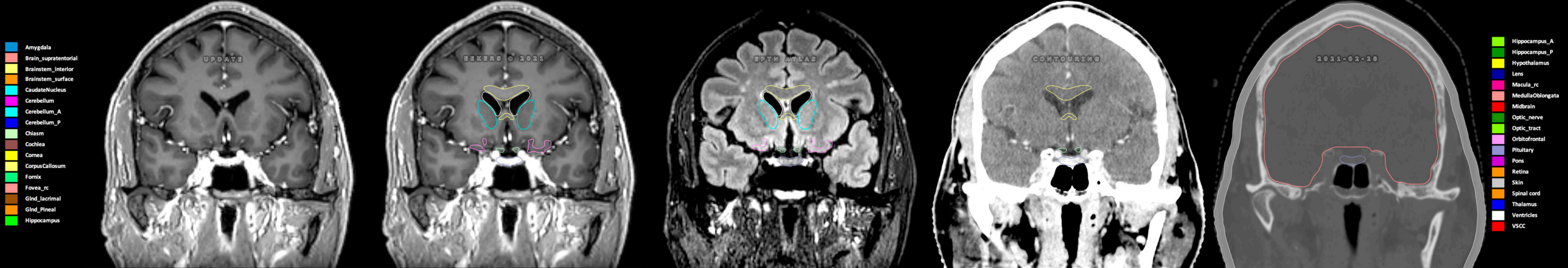
Amygdala
Brain_supratentorial
Brainstem_interior
Brainstem_surface
CaudateNucleus
Cerebellum
Cerebellum_A
Cerebellum_P
Chiasm
Cochlea
Cornea
CorpusCallosum
Fornix
Fovea_rc
Glnd_lacrimal
Glnd_Pineal
Hippocampus
UPDATE
EKERS © 2021
EPTH ATLAS
CONTOURING
2021-02-28
Hippocampus_A
Hippocampus_P
Hypothalamus
Lens
Macula_rc
MedullaOblongata
Midbrain
Optic_nerve
Optic_tract
Orbitofrontal
Pituitary
Pons
Retina
Skin
Spinal cord
Thalamus
Ventricles
VSCC

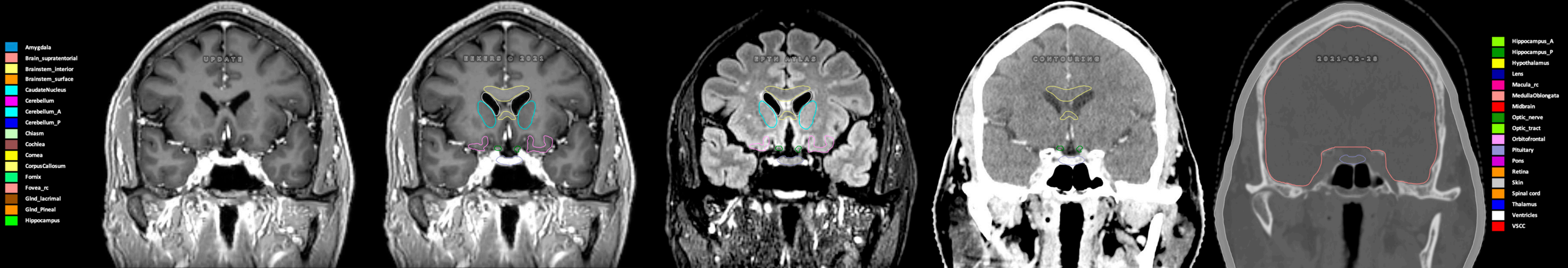
Amygdala
Brain_supratentorial
Brainstem_interior
Brainstem_surface
CaudateNucleus
Cerebellum
Cerebellum_A
Cerebellum_P
Chiasm
Cochlea
Cornea
CorpusCallosum
Fornix
Fovea_rc
Glnd_lacrimal
Glnd_Pineal
Hippocampus
UPDATE
EKERS © 2021
EPTH ATLAS
CONTOURING
2021-02-28
Hippocampus_A
Hippocampus_P
Hypothalamus
Lens
Macula_rc
MedullaOblongata
Midbrain
Optic_nerve
Optic_tract
Orbitofrontal
Pituitary
Pons
Retina
Skin
Spinal cord
Thalamus
Ventricles
VSCC

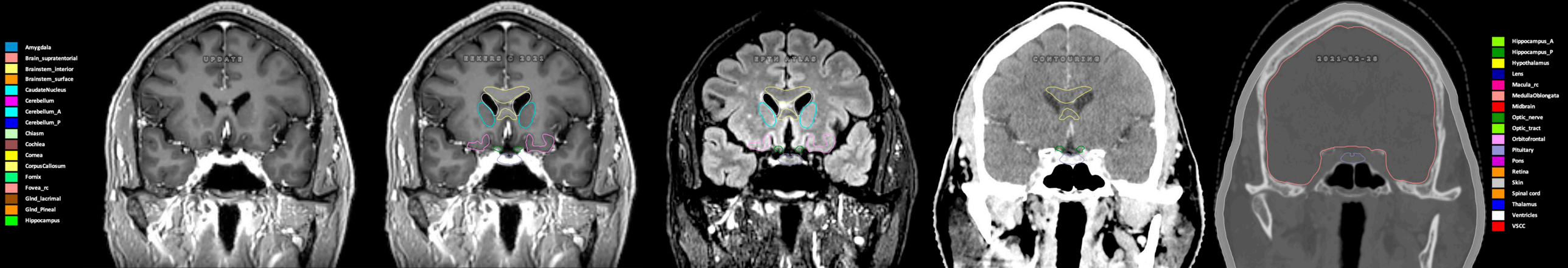
Amygdala
Brain_supratentorial
Brainstem_interior
Brainstem_surface
CaudateNucleus
Cerebellum
Cerebellum_A
Cerebellum_P
Chiasm
Cochlea
Cornea
CorpusCallosum
Fornix
Fovea_rc
Glnd_lacrimal
Glnd_Pineal
Hippocampus
UPDATE
EEKERS © 2021
EPTN ATLAS
CONTOURING
2021-02-28
Hippocampus_A
Hippocampus_P
Hypothalamus
Lens
Macula_rc
MedullaOblongata
Midbrain
Optic_nerve
Optic_tract
Orbitofrontal
Pituitary
Pons
Retina
Skin
Spinal cord
Thalamus
Ventricles
VSCC

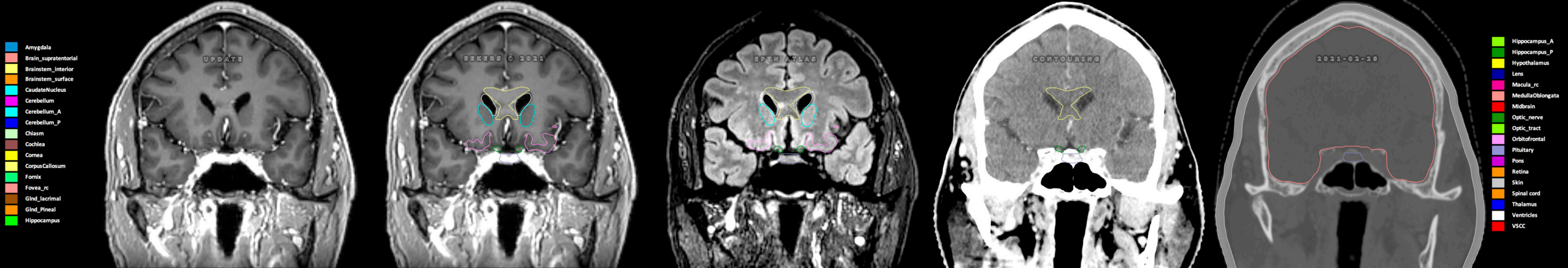
Amygdala
Brain_supratentorial
Brainstem_interior
Brainstem_surface
CaudateNucleus
Cerebellum
Cerebellum_A
Cerebellum_P
Chiasm
Cochlea
Cornea
CorpusCallosum
Fornix
Fovea_rc
Glnd_lacrimal
Glnd_Pineal
Hippocampus
UPDATE
EEKERS © 2021
EPTN ATLAS
CONTOURING
2021-02-28
Hippocampus_A
Hippocampus_P
Hypothalamus
Lens
Macula_rc
MedullaOblongata
Midbrain
Optic_nerve
Optic_tract
Orbitofrontal
Pituitary
Pons
Retina
Skin
Spinal cord
Thalamus
Ventricles
VSCC

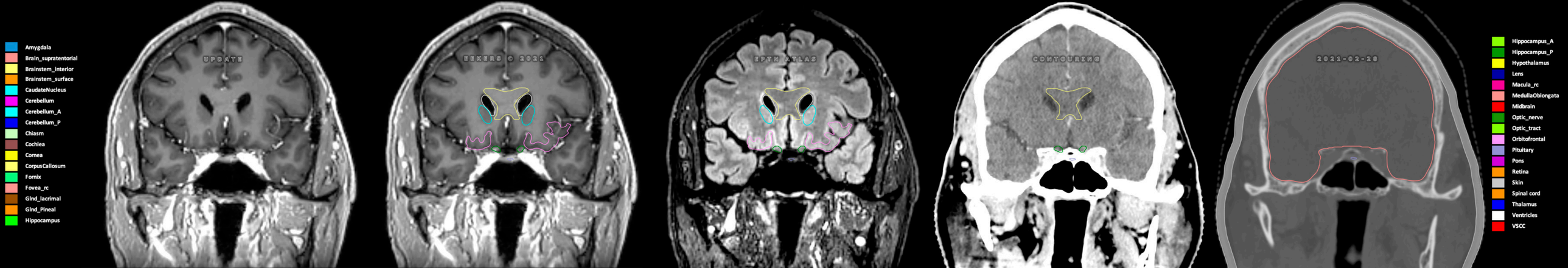
Amygdala
Brain_supratentorial
Brainstem_interior
Brainstem_surface
CaudateNucleus
Cerebellum
Cerebellum_A
Cerebellum_P
Chiasm
Cochlea
Cornea
CorpusCallosum
Fornix
Fovea_rc
Glnd_lacrimal
Glnd_Pineal
Hippocampus
UPDATE
EEKERS © 2021
EPTN ATLAS
CONTOURING
2021-02-28
Hippocampus_A
Hippocampus_P
Hypothalamus
Lens
Macula_rc
MedullaOblongata
Midbrain
Optic_nerve
Optic_tract
Orbitofrontal
Pituitary
Pons
Retina
Skin
Spinal cord
Thalamus
Ventricles
VSCC

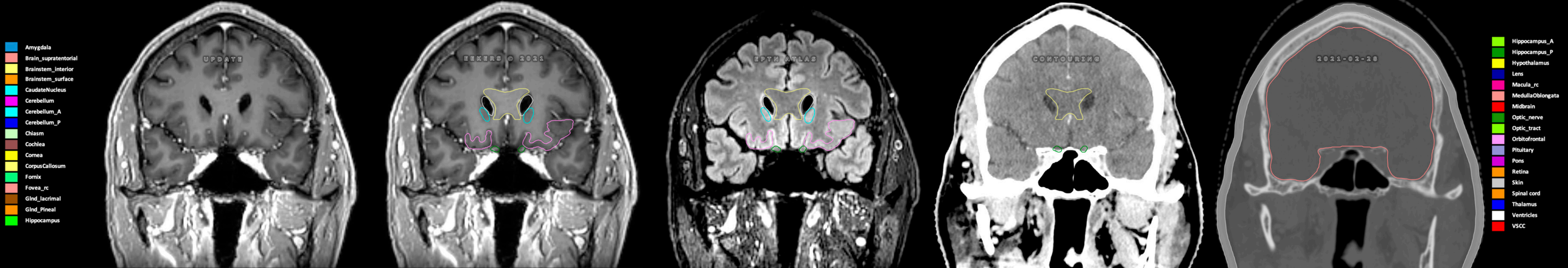
Amygdala
Brain_supratentorial
Brainstem_interior
Brainstem_surface
CaudateNucleus
Cerebellum
Cerebellum_A
Cerebellum_P
Chiasm
Cochlea
Cornea
CorpusCallosum
Fornix
Fovea_rc
Glnd_lacrimal
Glnd_Pineal
Hippocampus
UPDATE
EEKERS © 2021
EPTH ATLAS
CONTOURING
2021-02-28
Hippocampus_A
Hippocampus_P
Hypothalamus
Lens
Macula_rc
MedullaOblongata
Midbrain
Optic_nerve
Optic_tract
Orbitofrontal
Pituitary
Pons
Retina
Skin
Spinal cord
Thalamus
Ventricles
VSCC

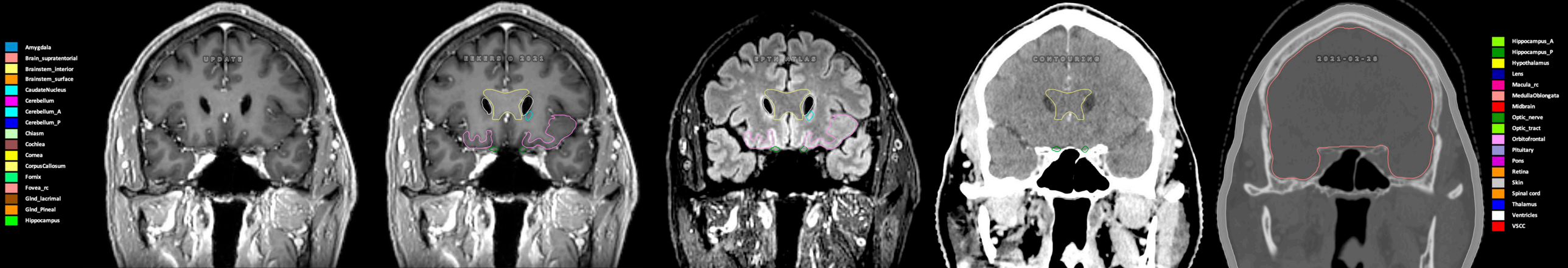
Amygdala
Brain_supratentorial
Brainstem_interior
Brainstem_surface
CaudateNucleus
Cerebellum
Cerebellum_A
Cerebellum_P
Chiasm
Cochlea
Cornea
CorpusCallosum
Fornix
Fovea_rc
Glnd_lacrimal
Glnd_Pineal
Hippocampus
UPDATE
EKERS © 2021
EPTH ATLAS
CONTOURING
2021-02-28
Hippocampus_A
Hippocampus_P
Hypothalamus
Lens
Macula_rc
MedullaOblongata
Midbrain
Optic_nerve
Optic_tract
Orbitofrontal
Pituitary
Pons
Retina
Skin
Spinal cord
Thalamus
Ventricles
VSCC

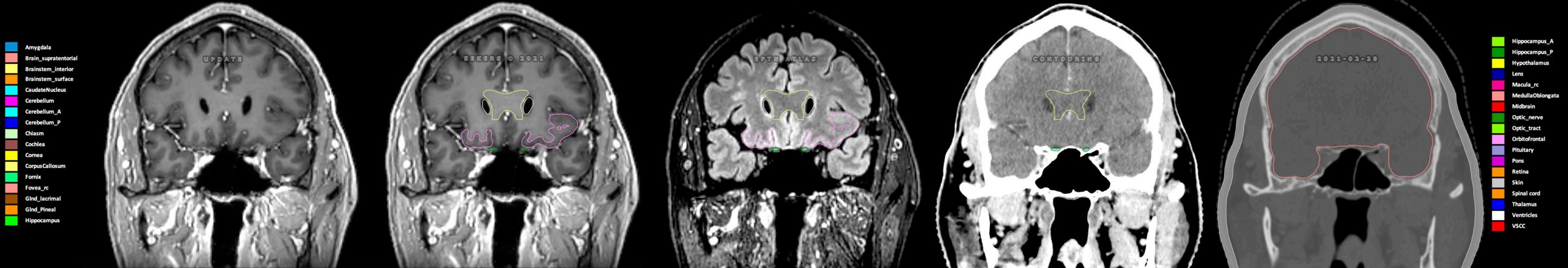
Amygdala
Brain_supratentorial
Brainstem_interior
Brainstem_surface
CaudateNucleus
Cerebellum
Cerebellum_A
Cerebellum_P
Chiasm
Cochlea
Cornea
CorpusCallosum
Fornix
Fovea_rc
Glnd_lacrimal
Glnd_Pineal
Hippocampus
UPDATE
EEKERS © 2021
EPTH ATLAS
CONTOURING
2021-02-28
Hippocampus_A
Hippocampus_P
Hypothalamus
Lens
Macula_rc
MedullaOblongata
Midbrain
Optic_nerve
Optic_tract
Orbitofrontal
Pituitary
Pons
Retina
Skin
Spinal cord
Thalamus
Ventricles
VSCC

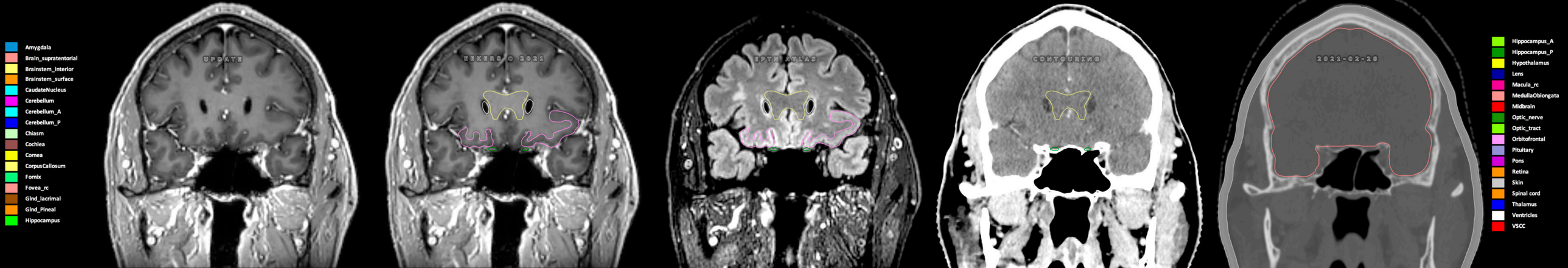
Amygdala
Brain_supratentorial
Brainstem_interior
Brainstem_surface
CaudateNucleus
Cerebellum
Cerebellum_A
Cerebellum_P
Chiasm
Cochlea
Cornea
CorpusCallosum
Fornix
Fovea_rc
Glnd_lacrimal
Glnd_Pineal
Hippocampus
UPDATE
EEKERS © 2021
EPTH ATLAS
CONTOURING
2021-02-28
Hippocampus_A
Hippocampus_P
Hypothalamus
Lens
Macula_rc
MedullaOblongata
Midbrain
Optic_nerve
Optic_tract
Orbitofrontal
Pituitary
Pons
Retina
Skin
Spinal cord
Thalamus
Ventricles
VSCC

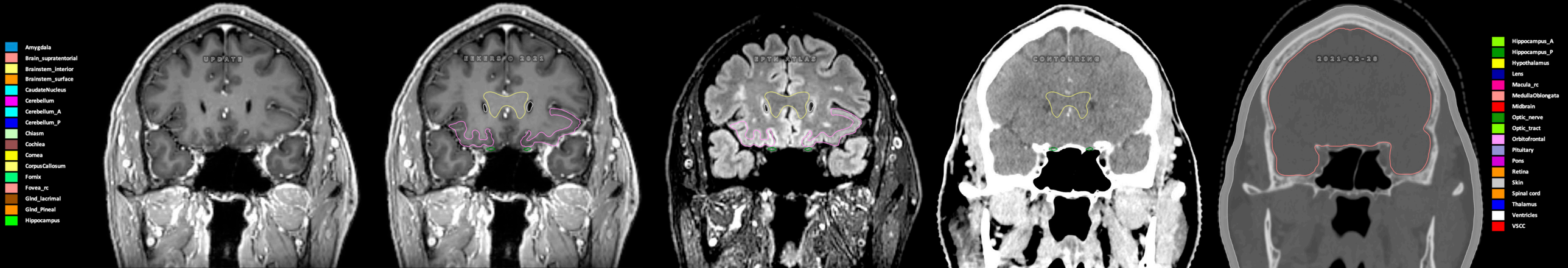
Amygdala
Brain_supratentorial
Brainstem_interior
Brainstem_surface
CaudateNucleus
Cerebellum
Cerebellum_A
Cerebellum_P
Chiasm
Cochlea
Cornea
CorpusCallosum
Fornix
Fovea_rc
Glnd_lacrimal
Glnd_Pineal
Hippocampus
UPDATE
EEKERS 0 2021
UPTH ATLAS
CONTOURING
2021-02-28
Hippocampus_A
Hippocampus_P
Hypothalamus
Lens
Macula_rc
MedullaOblongata
Midbrain
Optic_nerve
Optic_tract
Orbitofrontal
Pituitary
Pons
Retina
Skin
Spinal cord
Thalamus
Ventricles
VSCC

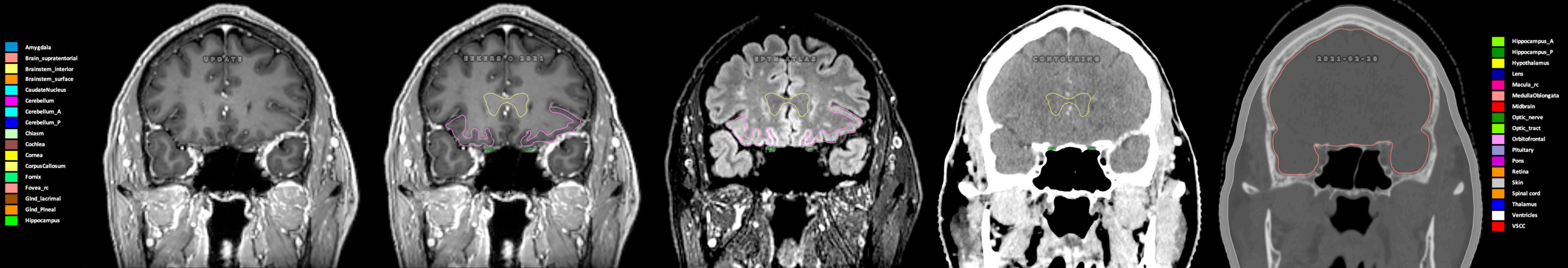
Amygdala
Brain_supratentorial
Brainstem_interior
Brainstem_surface
CaudateNucleus
Cerebellum
Cerebellum_A
Cerebellum_P
Chiasm
Cochlea
Cornea
CorpusCallosum
Fornix
Fovea_rc
Gland_lacrimal
Gland_Pineal
Hippocampus
UPDATE
EEKERS © 2021
EPTN ATLAS
CONTOURING
2021-02-28
Hippocampus_A
Hippocampus_P
Hypothalamus
Lens
Macula_rc
MedullaOblongata
Midbrain
Optic_nerve
Optic_tract
Orbitofrontal
Pituitary
Pons
Retina
Skin
Spinal cord
Thalamus
Ventricles
VSCC

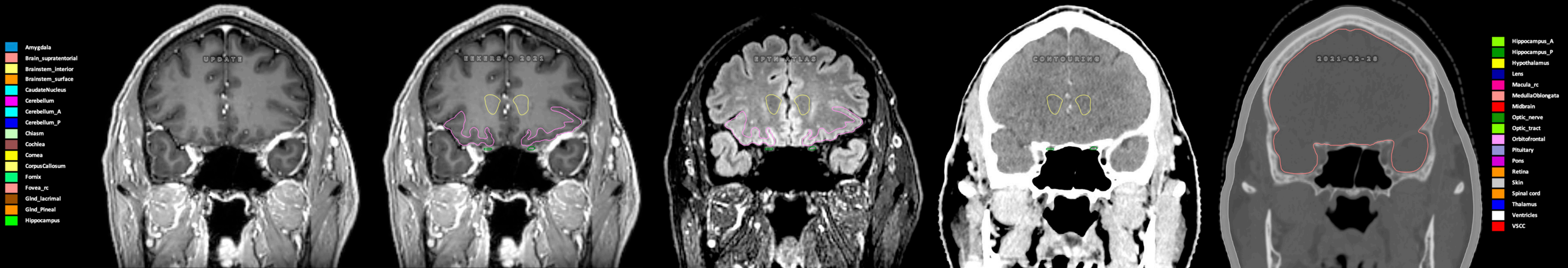
Amygdala
Brain_supratentorial
Brainstem_interior
Brainstem_surface
CaudateNucleus
Cerebellum
Cerebellum_A
Cerebellum_P
Chiasm
Cochlea
Cornea
CorpusCallosum
Fornix
Fovea_rc
Glnd_lacrimal
Glnd_Pineal
Hippocampus
UPDATE
EKERS © 2021
EPTH ATLAS
CONTOURING
2021-02-28
Hippocampus_A
Hippocampus_P
Hypothalamus
Lens
Macula_rc
MedullaOblongata
Midbrain
Optic_nerve
Optic_tract
Orbitofrontal
Pituitary
Pons
Retina
Skin
Spinal cord
Thalamus
Ventricles
VSCC

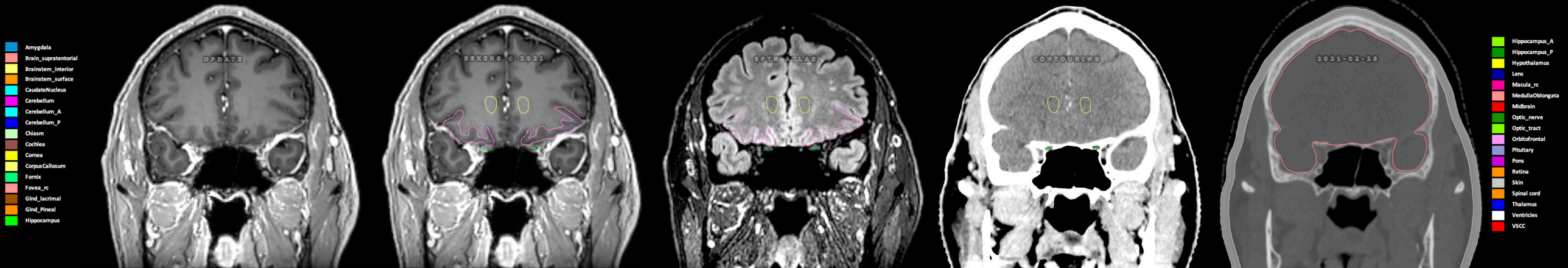
Amygdala
Brain_supratentorial
Brainstem_interior
Brainstem_surface
CaudateNucleus
Cerebellum
Cerebellum_A
Cerebellum_P
Chiasm
Cochlea
Cornea
CorpusCallosum
Fornix
Fovea_rc
Glnd_lacrimal
Glnd_Pineal
Hippocampus
UPDATE
EKERS © 2021
EPTN ATLAS
CONTOURING
2021-02-28
Hippocampus_A
Hippocampus_P
Hypothalamus
Lens
Macula_rc
MedullaOblongata
Midbrain
Optic_nerve
Optic_tract
Orbitofrontal
Pituitary
Pons
Retina
Skin
Spinal cord
Thalamus
Ventricles
VSCC

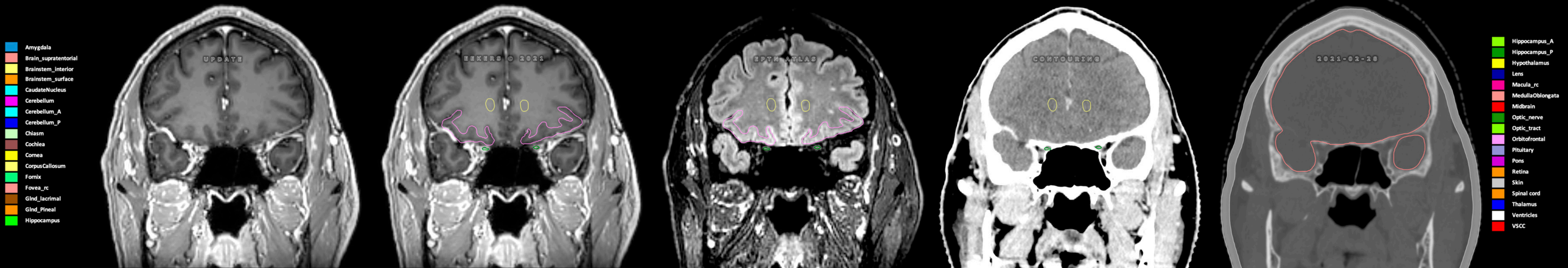
Amygdala
Brain_supratentorial
Brainstem_interior
Brainstem_surface
CaudateNucleus
Cerebellum
Cerebellum_A
Cerebellum_P
Chiasm
Cochlea
Cornea
CorpusCallosum
Fornix
Fovea_rc
Glnd_lacrimal
Glnd_Pineal
Hippocampus
UPDATE
EKERS © 2021
EPTH ATLAS
CONTOURING
2021-02-28
Hippocampus_A
Hippocampus_P
Hypothalamus
Lens
Macula_rc
MedullaOblongata
Midbrain
Optic_nerve
Optic_tract
Orbitofrontal
Pituitary
Pons
Retina
Skin
Spinal cord
Thalamus
Ventricles
VSCC

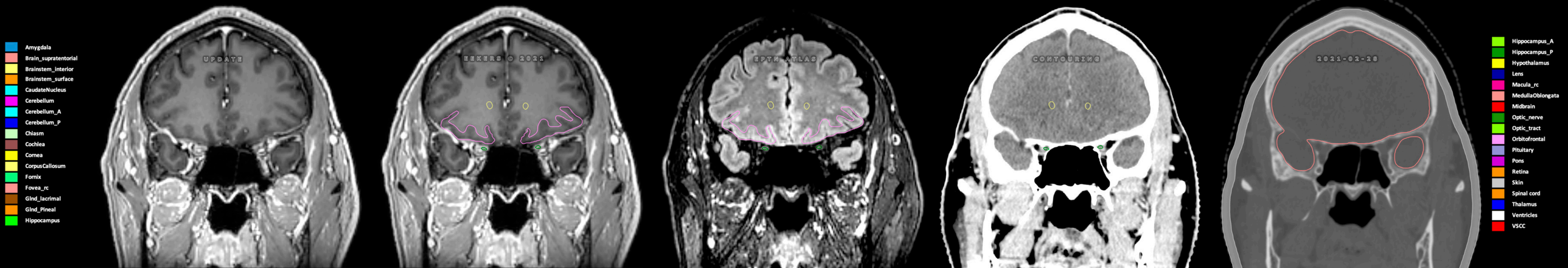
Amygdala
Brain_supratentorial
Brainstem_interior
Brainstem_surface
CaudateNucleus
Cerebellum
Cerebellum_A
Cerebellum_P
Chiasm
Cochlea
Cornea
CorpusCallosum
Fornix
Fovea_rc
Glnd_lacrimal
Glnd_Pineal
Hippocampus
UPDATE
EKERS © 2021
EPTH ATLAS
CONTOURING
2021-02-28
Hippocampus_A
Hippocampus_P
Hypothalamus
Lens
Macula_rc
MedullaOblongata
Midbrain
Optic_nerve
Optic_tract
Orbitofrontal
Pituitary
Pons
Retina
Skin
Spinal cord
Thalamus
Ventricles
VSCC

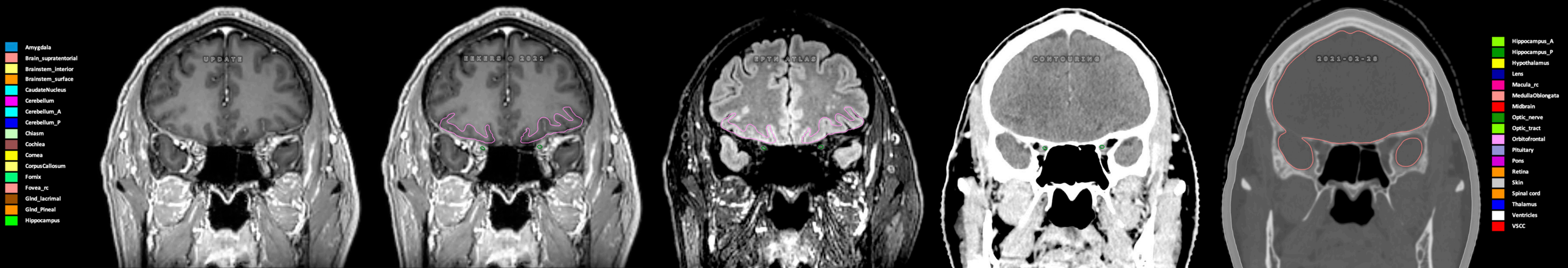
Amygdala
Brain_supratentorial
Brainstem_interior
Brainstem_surface
CaudateNucleus
Cerebellum
Cerebellum_A
Cerebellum_P
Chiasm
Cochlea
Cornea
CorpusCallosum
Fornix
Fovea_rc
Glnd_lacrimal
Glnd_Pineal
Hippocampus
UPDATE
EKERS © 2021
EPTH ATLAS
CONTOURING
2021-02-28
Hippocampus_A
Hippocampus_P
Hypothalamus
Lens
Macula_rc
MedullaOblongata
Midbrain
Optic_nerve
Optic_tract
Orbitofrontal
Pituitary
Pons
Retina
Skin
Spinal cord
Thalamus
Ventricles
VSCC

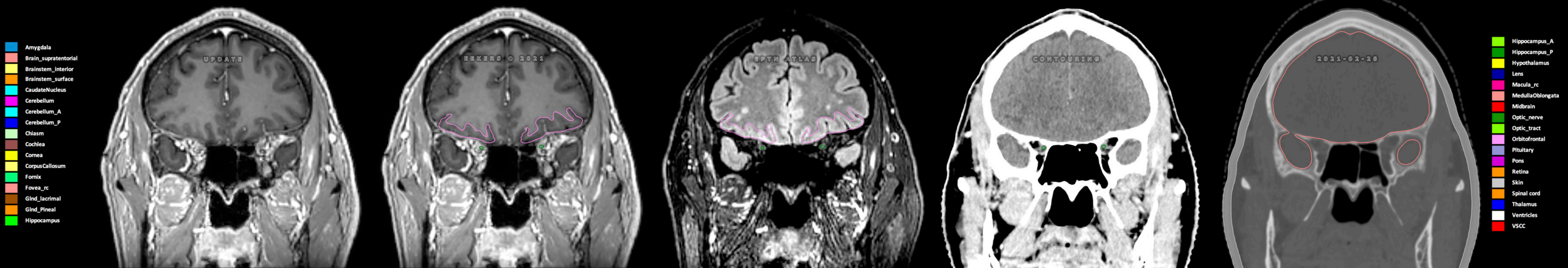
Amygdala
Brain_supratentorial
Brainstem_interior
Brainstem_surface
CaudateNucleus
Cerebellum
Cerebellum_A
Cerebellum_P
Chiasm
Cochlea
Cornea
CorpusCallosum
Fornix
Fovea_rc
Glnd_lacrimal
Glnd_Pineal
Hippocampus
UPDATE
EKERS © 2021
EPTH ATLAS
CONTOURING
2021-02-28
Hippocampus_A
Hippocampus_P
Hypothalamus
Lens
Macula_rc
MedullaOblongata
Midbrain
Optic_nerve
Optic_tract
Orbitofrontal
Pituitary
Pons
Retina
Skin
Spinal cord
Thalamus
Ventricles
VSCC

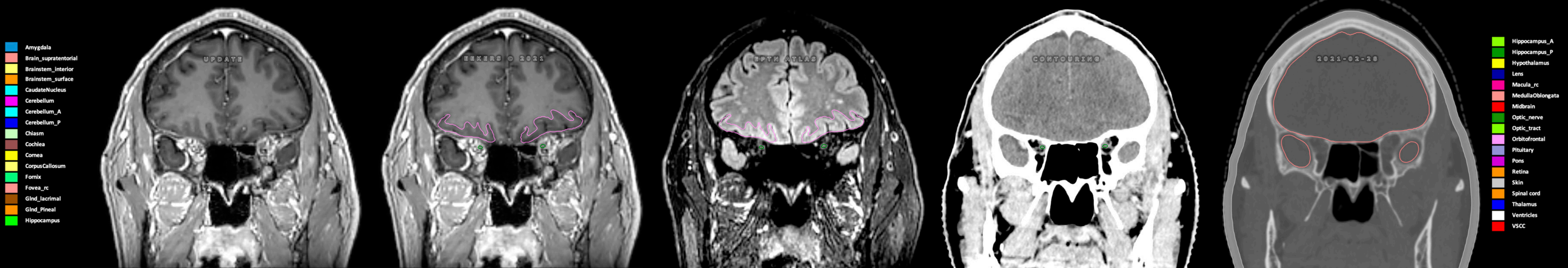
Amygdala
Brain_supratentorial
Brainstem_interior
Brainstem_surface
CaudateNucleus
Cerebellum
Cerebellum_A
Cerebellum_P
Chiasm
Cochlea
Cornea
CorpusCallosum
Fornix
Fovea_rc
Glnd_lacrimal
Glnd_Pineal
Hippocampus
UPDATE
EKERS © 2021
EPTH ATLAS
CONTOURING
2021-02-28
Hippocampus_A
Hippocampus_P
Hypothalamus
Lens
Macula_rc
MedullaOblongata
Midbrain
Optic_nerve
Optic_tract
Orbitofrontal
Pituitary
Pons
Retina
Skin
Spinal cord
Thalamus
Ventricles
VSCC

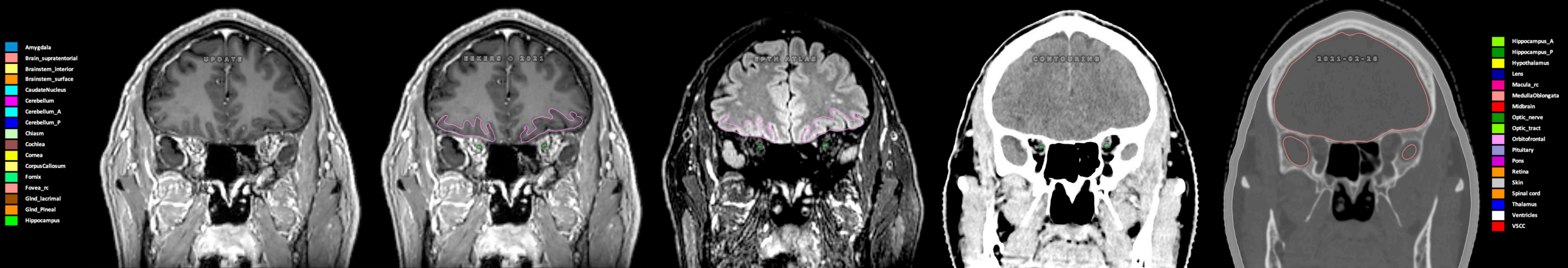
Amygdala
Brain_supratentorial
Brainstem_interior
Brainstem_surface
CaudateNucleus
Cerebellum
Cerebellum_A
Cerebellum_P
Chiasm
Cochlea
Cornea
CorpusCallosum
Fornix
Fovea_rc
Glnd_lacrimal
Glnd_Pineal
Hippocampus
UPDATE
EEKERS © 2021
EPTH ATLAS
CONTOURING
2021-02-28
Hippocampus_A
Hippocampus_P
Hypothalamus
Lens
Macula_rc
MedullaOblongata
Midbrain
Optic_nerve
Optic_tract
Orbitofrontal
Pituitary
Pons
Retina
Skin
Spinal cord
Thalamus
Ventricles
VSCC

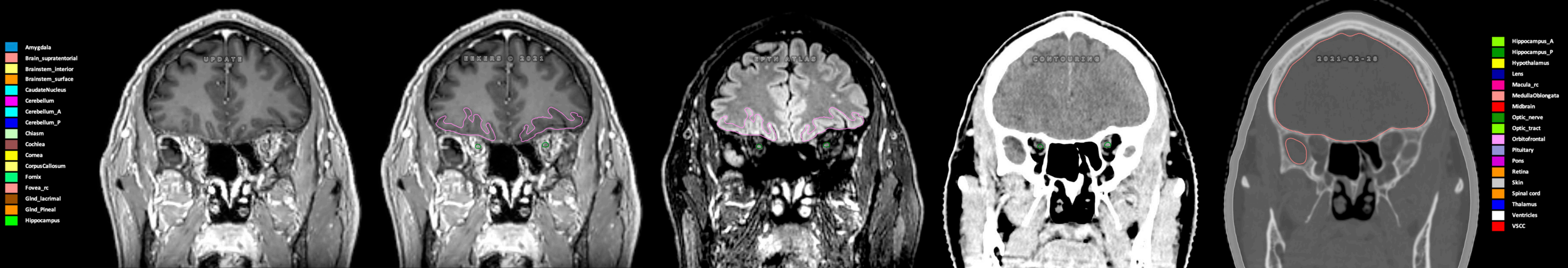
Amygdala
Brain_supratentorial
Brainstem_interior
Brainstem_surface
CaudateNucleus
Cerebellum
Cerebellum_A
Cerebellum_P
Chiasm
Cochlea
Cornea
CorpusCallosum
Fornix
Fovea_rc
Glnd_lacrimal
Glnd_Pineal
Hippocampus
UPDATE
EKERS © 2021
EPTH ATLAS
CONTOURING
2021-02-28
Hippocampus_A
Hippocampus_P
Hypothalamus
Lens
Macula_rc
MedullaOblongata
Midbrain
Optic_nerve
Optic_tract
Orbitofrontal
Pituitary
Pons
Retina
Skin
Spinal cord
Thalamus
Ventricles
VSCC

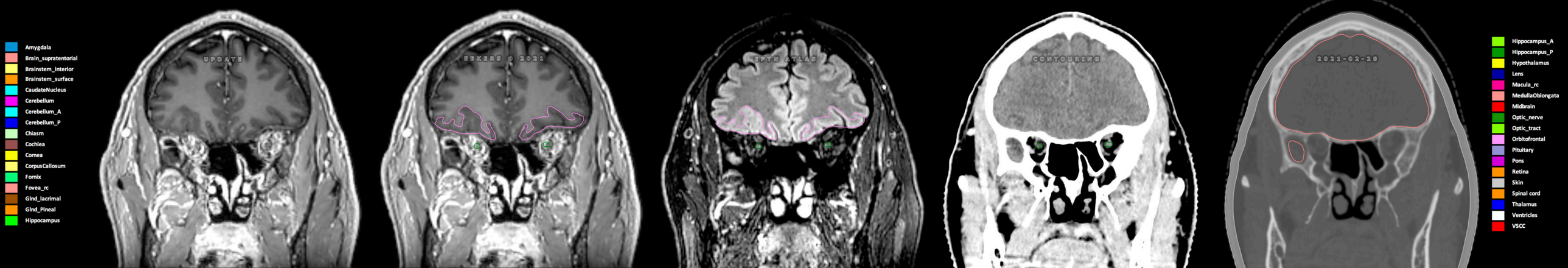
Amygdala
Brain_supratentorial
Brainstem_interior
Brainstem_surface
CaudateNucleus
Cerebellum
Cerebellum_A
Cerebellum_P
Chiasm
Cochlea
Cornea
CorpusCallosum
Fornix
Fovea_rc
Gland_lacrimal
Gland_Pineal
Hippocampus
UPDATE
EEKERS © 2021
EPTN ATLAS
CONTOURING
2021-02-28
Hippocampus_A
Hippocampus_P
Hypothalamus
Lens
Macula_rc
MedullaOblongata
Midbrain
Optic_nerve
Optic_tract
Orbitofrontal
Pituitary
Pons
Retina
Skin
Spinal cord
Thalamus
Ventricles
VSCC

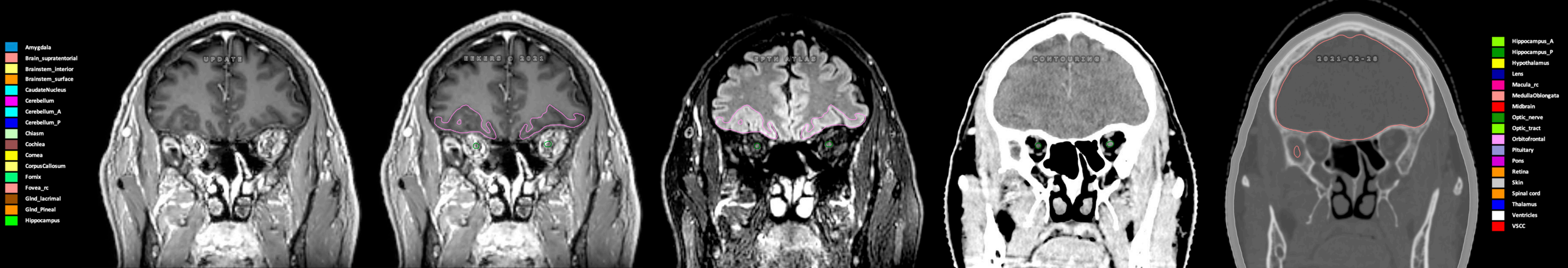
Amygdala
Brain_supratentorial
Brainstem_interior
Brainstem_surface
CaudateNucleus
Cerebellum
Cerebellum_A
Cerebellum_P
Chiasm
Cochlea
Cornea
CorpusCallosum
Fornix
Fovea_rc
Glnd_lacrimal
Glnd_Pineal
Hippocampus
UPDATE
EEKERS © 2021
TPTH ATLAS
CONTOURING
2021-02-28
Hippocampus_A
Hippocampus_P
Hypothalamus
Lens
Macula_rc
MedullaOblongata
Midbrain
Optic_nerve
Optic_tract
Orbitofrontal
Pituitary
Pons
Retina
Skin
Spinal cord
Thalamus
Ventricles
VSCC

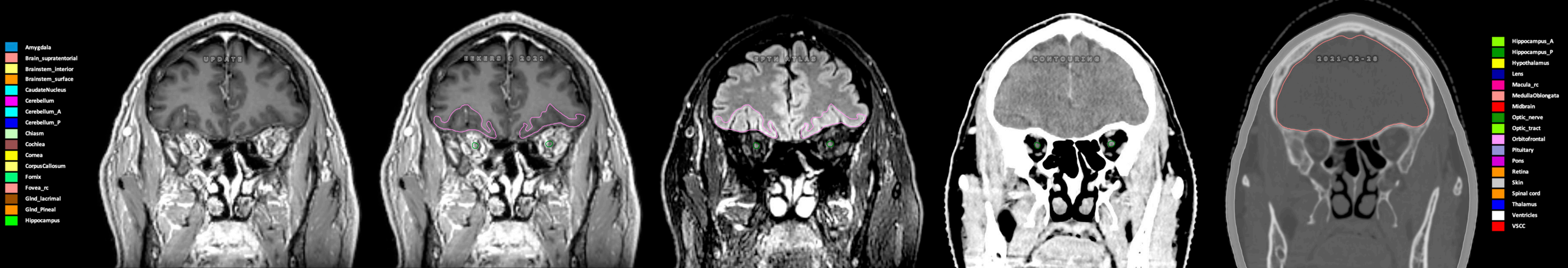
Amygdala
Brain_supratentorial
Brainstem_interior
Brainstem_surface
CaudateNucleus
Cerebellum
Cerebellum_A
Cerebellum_P
Chiasm
Cochlea
Cornea
CorpusCallosum
Fornix
Fovea_rc
Glnd_lacrimal
Glnd_Pineal
Hippocampus
UPDATE
EKERS © 2021
EPTH ATLAS
CONTOURING
2021-02-28
Hippocampus_A
Hippocampus_P
Hypothalamus
Lens
Macula_rc
MedullaOblongata
Midbrain
Optic_nerve
Optic_tract
Orbitofrontal
Pituitary
Pons
Retina
Skin
Spinal cord
Thalamus
Ventricles
VSCC

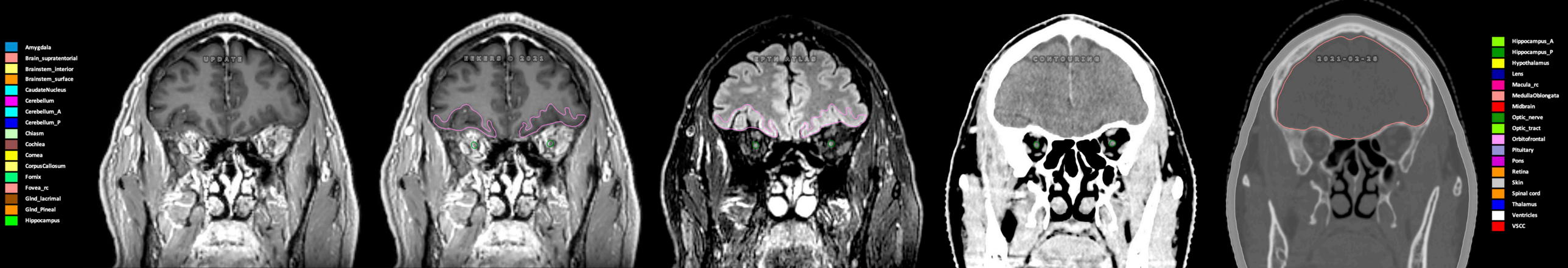
Amygdala
Brain_supratentorial
Brainstem_interior
Brainstem_surface
CaudateNucleus
Cerebellum
Cerebellum_A
Cerebellum_P
Chiasm
Cochlea
Cornea
CorpusCallosum
Fornix
Fovea_rc
Glnd_lacrimal
Glnd_Pineal
Hippocampus
UPDATE
EKERS © 2021
EPTH ATLAS
CONTOURING
2021-02-28
Hippocampus_A
Hippocampus_P
Hypothalamus
Lens
Macula_rc
MedullaOblongata
Midbrain
Optic_nerve
Optic_tract
Orbitofrontal
Pituitary
Pons
Retina
Skin
Spinal cord
Thalamus
Ventricles
VSCC

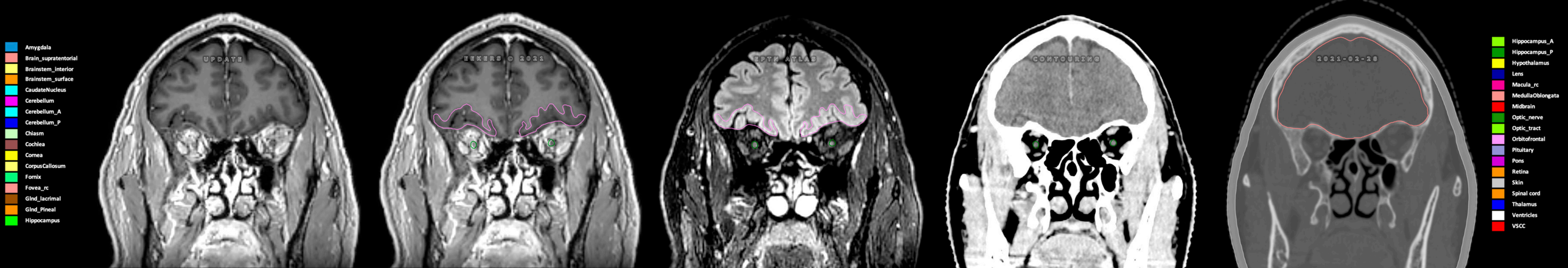
Amygdala
Brain_supratentorial
Brainstem_interior
Brainstem_surface
CaudateNucleus
Cerebellum
Cerebellum_A
Cerebellum_P
Chiasm
Cochlea
Cornea
CorpusCallosum
Fornix
Fovea_rc
Glnd_lacrimal
Glnd_Pineal
Hippocampus
UPDATE
EKERS © 2021
EPTN ATLAS
CONTOURING
2021-02-28
Hippocampus_A
Hippocampus_P
Hypothalamus
Lens
Macula_rc
MedullaOblongata
Midbrain
Optic_nerve
Optic_tract
Orbitofrontal
Pituitary
Pons
Retina
Skin
Spinal cord
Thalamus
Ventricles
VSCC

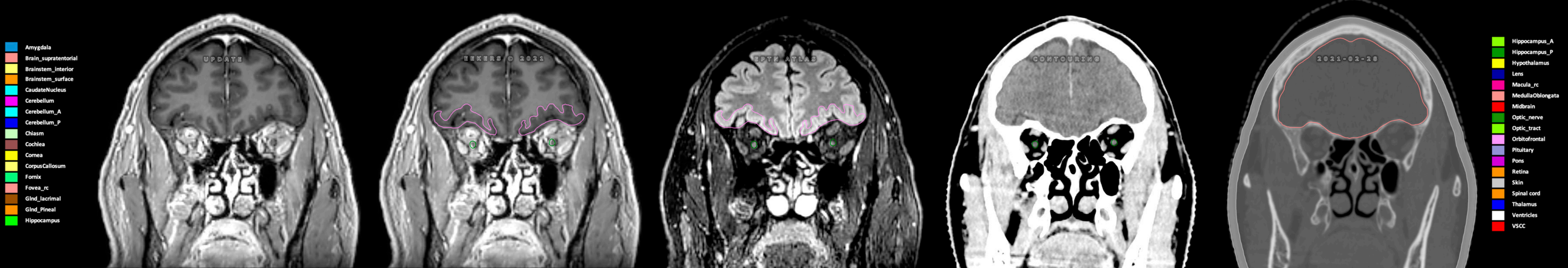
Amygdala
Brain_supratentorial
Brainstem_interior
Brainstem_surface
CaudateNucleus
Cerebellum
Cerebellum_A
Cerebellum_P
Chiasm
Cochlea
Cornea
CorpusCallosum
Fornix
Fovea_rc
Glnd_lacrimal
Glnd_Pineal
Hippocampus
UPDATE
EEKERS © 2021
UPTX ATLAS
CONTOURING
2021-02-28
Hippocampus_A
Hippocampus_P
Hypothalamus
Lens
Macula_rc
MedullaOblongata
Midbrain
Optic_nerve
Optic_tract
Orbitofrontal
Pituitary
Pons
Retina
Skin
Spinal cord
Thalamus
Ventricles
VSCC

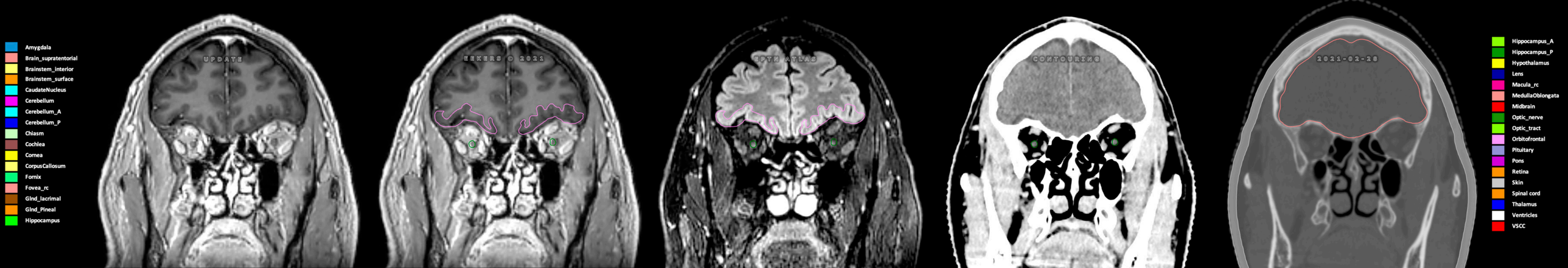
Amygdala
Brain_supratentorial
Brainstem_interior
Brainstem_surface
CaudateNucleus
Cerebellum
Cerebellum_A
Cerebellum_P
Chiasm
Cochlea
Cornea
CorpusCallosum
Fornix
Fovea_rc
Glnd_lacrimal
Glnd_Pineal
Hippocampus
UPDATE
EEKERS © 2021
19TH ATLAS
CONTOURING
2021-02-28
Hippocampus_A
Hippocampus_P
Hypothalamus
Lens
Macula_rc
MedullaOblongata
Midbrain
Optic_nerve
Optic_tract
Orbitofrontal
Pituitary
Pons
Retina
Skin
Spinal cord
Thalamus
Ventricles
VSCC

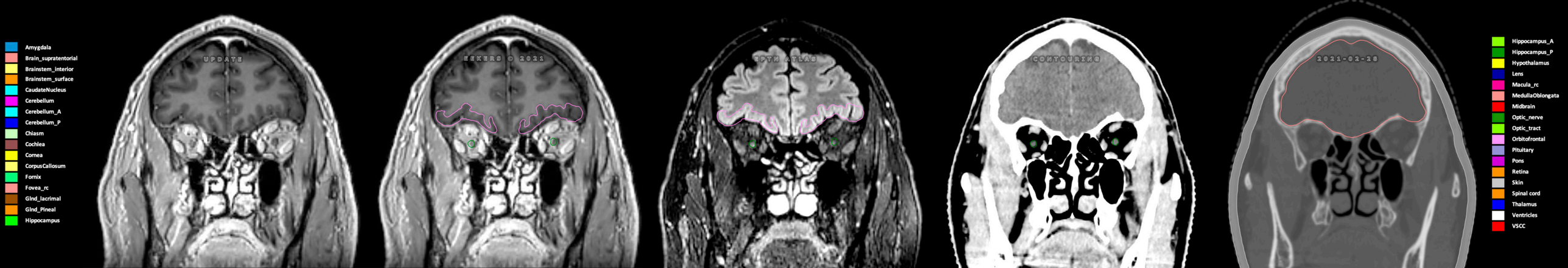
Amygdala
Brain_supratentorial
Brainstem_interior
Brainstem_surface
CaudateNucleus
Cerebellum
Cerebellum_A
Cerebellum_P
Chiasm
Cochlea
Cornea
CorpusCallosum
Fornix
Fovea_rc
Gland_lacrimal
Gland_Pineal
Hippocampus
UPDATE
EEKERS © 2021
IPTH ATLAS
CONTOURING
2021-02-28
Hippocampus_A
Hippocampus_P
Hypothalamus
Lens
Macula_rc
MedullaOblongata
Midbrain
Optic_nerve
Optic_tract
Orbitofrontal
Pituitary
Pons
Retina
Skin
Spinal cord
Thalamus
Ventricles
VSCC

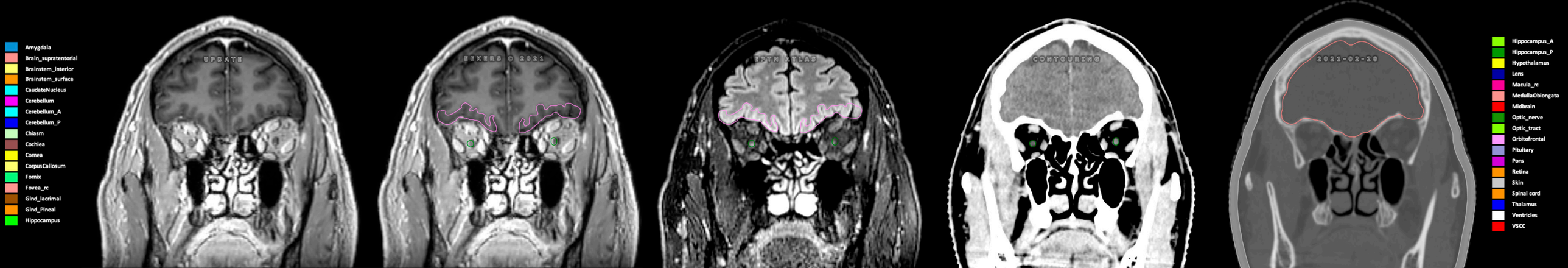
Amygdala
Brain_supratentorial
Brainstem_interior
Brainstem_surface
CaudateNucleus
Cerebellum
Cerebellum_A
Cerebellum_P
Chiasm
Cochlea
Cornea
CorpusCallosum
Fornix
Fovea_rc
Glnd_lacrimal
Glnd_Pineal
Hippocampus
UPDATE
EKERS © 2021
EPTH ATLAS
CONTOURING
2021-02-28
Hippocampus_A
Hippocampus_P
Hypothalamus
Lens
Macula_rc
MedullaOblongata
Midbrain
Optic_nerve
Optic_tract
Orbitofrontal
Pituitary
Pons
Retina
Skin
Spinal cord
Thalamus
Ventricles
VSCC

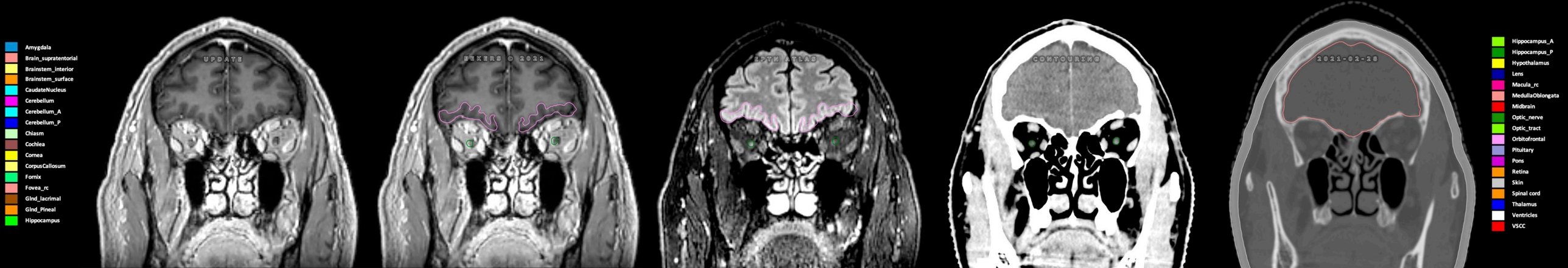
Amygdala
Brain_supratentorial
Brainstem_interior
Brainstem_surface
CaudateNucleus
Cerebellum
Cerebellum_A
Cerebellum_P
Chiasm
Cochlea
Cornea
CorpusCallosum
Fornix
Fovea_rc
Glnd_lacrimal
Glnd_Pineal
Hippocampus
UPDATE
EIKERS © 2021
EPTN ATLAS
CONTOURING
2021-02-28
Hippocampus_A
Hippocampus_P
Hypothalamus
Lens
Macula_rc
MedullaOblongata
Midbrain
Optic_nerve
Optic_tract
Orbitofrontal
Pituitary
Pons
Retina
Skin
Spinal cord
Thalamus
Ventricles
VSCC

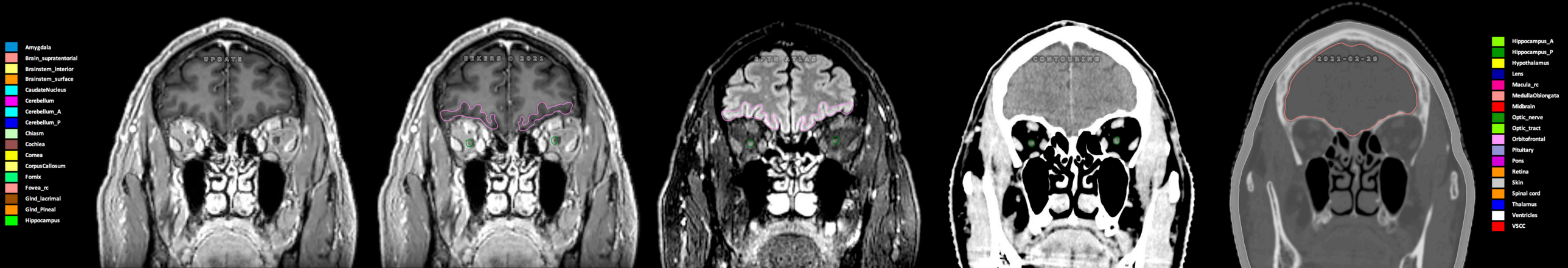
Amygdala
Brain_supratentorial
Brainstem_interior
Brainstem_surface
CaudateNucleus
Cerebellum
Cerebellum_A
Cerebellum_P
Chiasm
Cochlea
Cornea
CorpusCallosum
Fornix
Fovea_rc
Glnd_lacrimal
Glnd_Pineal
Hippocampus
UPDATE
EIKERS © 2021
EPTN ATLAS
CONTOURING
2021-02-28
Hippocampus_A
Hippocampus_P
Hypothalamus
Lens
Macula_rc
MedullaOblongata
Midbrain
Optic_nerve
Optic_tract
Orbitofrontal
Pituitary
Pons
Retina
Skin
Spinal cord
Thalamus
Ventricles
VSCC

Amygdala
Brain_supratentorial
Brainstem_interior
Brainstem_surface
CaudateNucleus
Cerebellum
Cerebellum_A
Cerebellum_P
Chiasm
Cochlea
Cornea
CorpusCallosum
Fornix
Fovea_rc
Gland_lacrimal
Gland_Pineal
Hippocampus
UPDATE
EKERS © 2021
ITH ATLAS
CONTOURING
2021-02-26
Hippocampus_A
Hippocampus_P
Hypothalamus
Lens
Macula_rc
MedullaOblongata
Midbrain
Optic_nerve
Optic_tract
Orbitofrontal
Pituitary
Pons
Retina
Skin
Spinal cord
Thalamus
Ventricles
VSCC

Amygdala
Brain_supratentorial
Brainstem_interior
Brainstem_surface
CaudateNucleus
Cerebellum
Cerebellum_A
Cerebellum_P
Chiasm
Cochlea
Cornea
CorpusCallosum
Fornix
Fovea_rc
Gland_lacrimal
Gland_Pineal
Hippocampus
UPDATE
EKERS © 2021
EPTN ATLAS
CONTOURING
2021-02-28
Hippocampus_A
Hippocampus_P
Hypothalamus
Lens
Macula_rc
MedullaOblongata
Midbrain
Optic_nerve
Optic_tract
Orbitofrontal
Pituitary
Pons
Retina
Skin
Spinal cord
Thalamus
Ventricles
VSCC

Amygdala
Brain_supratentorial
Brainstem_interior
Brainstem_surface
CaudateNucleus
Cerebellum
Cerebellum_A
Cerebellum_P
Chiasm
Cochlea
Cornea
CorpusCallosum
Fornix
Fovea_rc
Glnd_lacrimal
Glnd_Pineal
Hippocampus
UPDATE
EEKERS © 2021
EPTN ATLAS
CONTOURING
2021-02-28
Hippocampus_A
Hippocampus_P
Hypothalamus
Lens
Macula_rc
MedullaOblongata
Midbrain
Optic_nerve
Optic_tract
Orbitofrontal
Pituitary
Pons
Retina
Skin
Spinal cord
Thalamus
Ventricles
VSCC

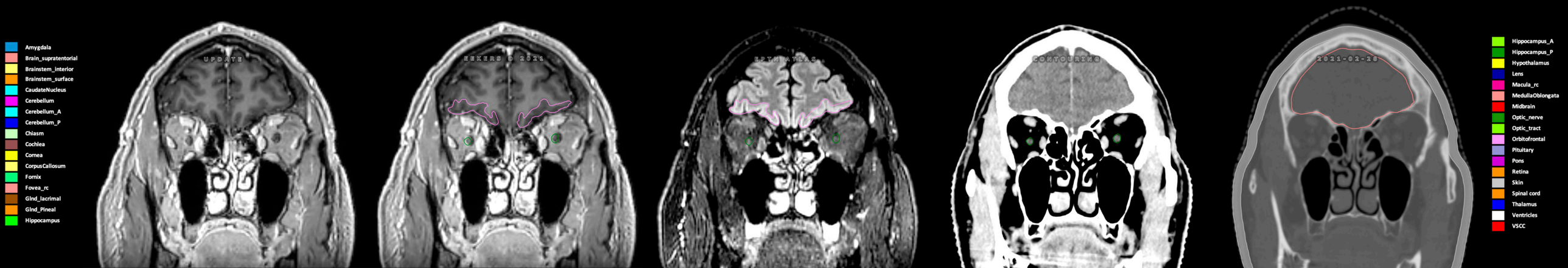
Amygdala
Brain_supratentorial
Brainstem_interior
Brainstem_surface
CaudateNucleus
Cerebellum
Cerebellum_A
Cerebellum_P
Chiasm
Cochlea
Cornea
CorpusCallosum
Fornix
Fovea_rc
Glnd_lacrimal
Glnd_Pineal
Hippocampus
UPDATE
EEKERS 2 2021
EPYMATAS
CONTOURING
2021-02-25
Hippocampus_A
Hippocampus_P
Hypothalamus
Lens
Macula_rc
MedullaOblongata
Midbrain
Optic_nerve
Optic_tract
Orbitofrontal
Pituitary
Pons
Retina
Skin
Spinal cord
Thalamus
Ventricles
VSCC

Amygdala
Brain_supratentorial
Brainstem_interior
Brainstem_surface
CaudateNucleus
Cerebellum
Cerebellum_A
Cerebellum_P
Chiasm
Cochlea
Cornea
CorpusCallosum
Fornix
Fovea_rc
Glnd_lacrimal
Glnd_Pineal
Hippocampus
UPDATE
EEKERS © 2021
EDYNATLAS
CONTOURING
2021-02-25
Hippocampus_A
Hippocampus_P
Hypothalamus
Lens
Macula_rc
MedullaOblongata
Midbrain
Optic_nerve
Optic_tract
Orbitofrontal
Pituitary
Pons
Retina
Skin
Spinal cord
Thalamus
Ventricles
VSCC

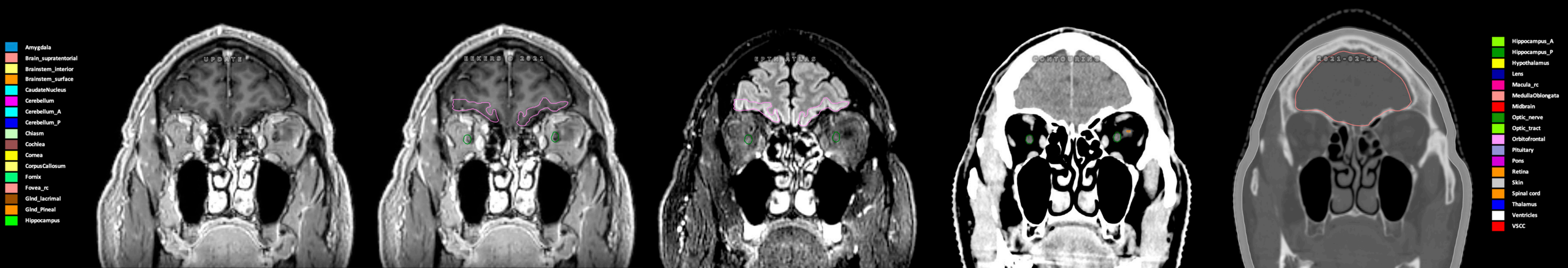
Amygdala
Brain_supratentorial
Brainstem_interior
Brainstem_surface
CaudateNucleus
Cerebellum
Cerebellum_A
Cerebellum_P
Chiasm
Cochlea
Cornea
CorpusCallosum
Fornix
Fovea_rc
Glnd_lacrimal
Glnd_Pineal
Hippocampus
UPDATE
EKERS © 2021
EPTHALAS
CONTOURING
2021-02-25
Hippocampus_A
Hippocampus_P
Hypothalamus
Lens
Macula_rc
MedullaOblongata
Midbrain
Optic_nerve
Optic_tract
Orbitofrontal
Pituitary
Pons
Retina
Skin
Spinal cord
Thalamus
Ventricles
VSCC

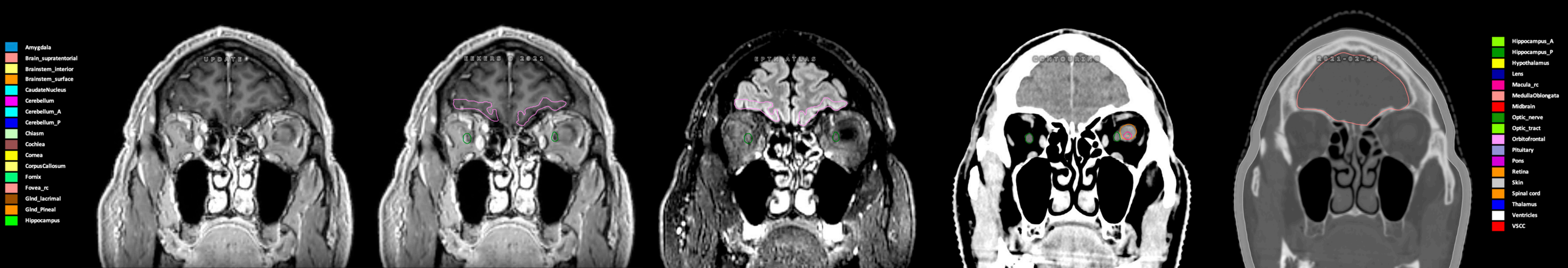
Amygdala
Brain_supratentorial
Brainstem_interior
Brainstem_surface
CaudateNucleus
Cerebellum
Cerebellum_A
Cerebellum_P
Chiasm
Cochlea
Cornea
CorpusCallosum
Fornix
Fovea_rc
Glnd_lacrimal
Glnd_Pineal
Hippocampus
UPDATE
EKERS 2021
EPTH ATLAS
CONTOURING
2021-02-25
Hippocampus_A
Hippocampus_P
Hypothalamus
Lens
Macula_rc
MedullaOblongata
Midbrain
Optic_nerve
Optic_tract
Orbitofrontal
Pituitary
Pons
Retina
Skin
Spinal cord
Thalamus
Ventricles
VSCC

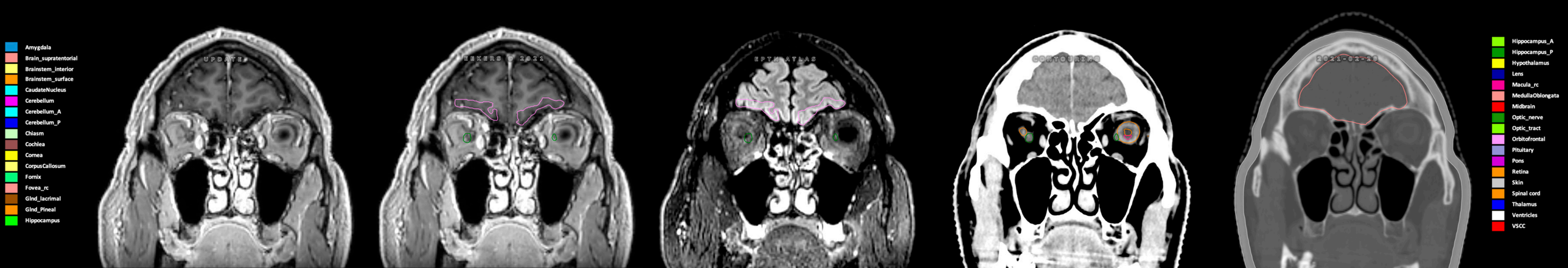
Amygdala
Brain_supratentorial
Brainstem_interior
Brainstem_surface
CaudateNucleus
Cerebellum
Cerebellum_A
Cerebellum_P
Chiasm
Cochlea
Cornea
CorpusCallosum
Fornix
Fovea_rc
Glnd_lacrimal
Glnd_Pineal
Hippocampus
UPDATE
EKERS | 2021
EPTH ATLAS
CONTOURING
2021-02-25
Hippocampus_A
Hippocampus_P
Hypothalamus
Lens
Macula_rc
MedullaOblongata
Midbrain
Optic_nerve
Optic_tract
Orbitofrontal
Pituitary
Pons
Retina
Skin
Spinal cord
Thalamus
Ventricles
VSCC

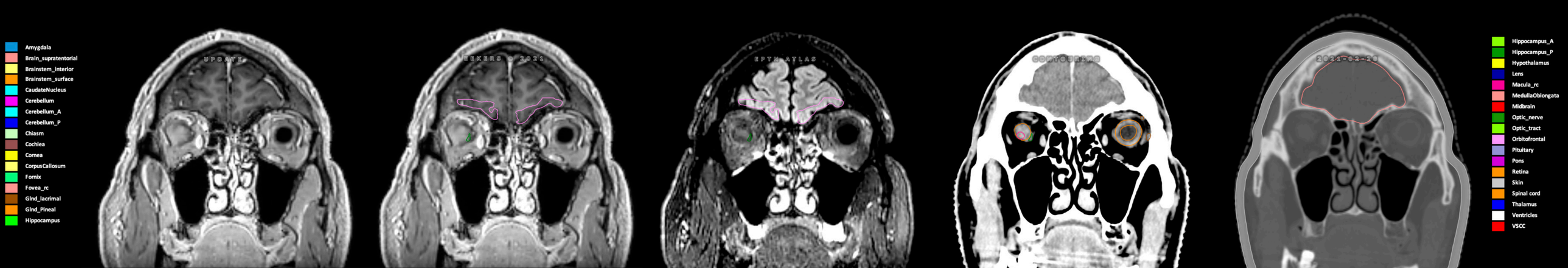
Amygdala
Brain_supratentorial
Brainstem_interior
Brainstem_surface
CaudateNucleus
Cerebellum
Cerebellum_A
Cerebellum_P
Chiasm
Cochlea
Cornea
CorpusCallosum
Fornix
Fovea_rc
Gland_lacrimal
Gland_Pineal
Hippocampus
UPDATE
EKERS 2021
EPTH ATLAS
CONTOURING
2021-04-28
Hippocampus_A
Hippocampus_P
Hypothalamus
Lens
Macula_rc
MedullaOblongata
Midbrain
Optic_nerve
Optic_tract
Orbitofrontal
Pituitary
Pons
Retina
Skin
Spinal cord
Thalamus
Ventricles
VSCC

Amygdala
Brain_supratentorial
Brainstem_interior
Brainstem_surface
CaudateNucleus
Cerebellum
Cerebellum_A
Cerebellum_P
Chiasm
Cochlea
Cornea
CorpusCallosum
Fornix
Fovea_rc
Glnd_lacrimal
Glnd_Pineal
Hippocampus
UPDATE
EKERS © 2021
EPTH ATLAS
CONTOURING
2021-02-26
Hippocampus_A
Hippocampus_P
Hypothalamus
Lens
Macula_rc
MedullaOblongata
Midbrain
Optic_nerve
Optic_tract
Orbitofrontal
Pituitary
Pons
Retina
Skin
Spinal cord
Thalamus
Ventricles
VSCC

Amygdala
Brain_supratentorial
Brainstem_interior
Brainstem_surface
CaudateNucleus
Cerebellum
Cerebellum_A
Cerebellum_P
Chiasm
Cochlea
Cornea
CorpusCallosum
Fornix
Fovea_rc
Glnd_lacrimal
Glnd_Pineal
Hippocampus
UPDATE
EKERS © 2021
EPTH ATLAS
CONTOURING
2021-02-26
Hippocampus_A
Hippocampus_P
Hypothalamus
Lens
Macula_rc
MedullaOblongata
Midbrain
Optic_nerve
Optic_tract
Orbitofrontal
Pituitary
Pons
Retina
Skin
Spinal cord
Thalamus
Ventricles
VSCC

Amygdala
Brain_supratentorial
Brainstem_interior
Brainstem_surface
CaudateNucleus
Cerebellum
Cerebellum_A
Cerebellum_P
Chiasm
Cochlea
Cornea
CorpusCallosum
Fornix
Fovea_rc
Gland_lacrimal
Gland_Pineal
Hippocampus
UPDATE
EKERS © 2021
EPTH ATLAS
CONTOURING
2021-02-26
Hippocampus_A
Hippocampus_P
Hypothalamus
Lens
Macula_rc
MedullaOblongata
Midbrain
Optic_nerve
Optic_tract
Orbitofrontal
Pituitary
Pons
Retina
Skin
Spinal cord
Thalamus
Ventricles
VSCC

Amygdala
Brain_supratentorial
Brainstem_interior
Brainstem_surface
CaudateNucleus
Cerebellum
Cerebellum_A
Cerebellum_P
Chiasm
Cochlea
Cornea
CorpusCallosum
Fornix
Fovea_rc
Glnd_lacrimal
Glnd_Pineal
Hippocampus
UPDATE
EIKERS © 2021
EPTH ATLAS
ONTOURING
2021-02-26
Hippocampus_A
Hippocampus_P
Hypothalamus
Lens
Macula_rc
MedullaOblongata
Midbrain
Optic_nerve
Optic_tract
Orbitofrontal
Pituitary
Pons
Retina
Skin
Spinal cord
Thalamus
Ventricles
VSCC

Amygdala
Brain_supratentorial
Brainstem_interior
Brainstem_surface
CaudateNucleus
Cerebellum
Cerebellum_A
Cerebellum_P
Chiasm
Cochlea
Cornea
CorpusCallosum
Fornix
Fovea_rc
Gland_lacrimal
Gland_Pineal
Hippocampus
UPDATE
EIKERS © 2021
EPTH ATLAS
CONTOURING
2021-02-28
Hippocampus_A
Hippocampus_P
Hypothalamus
Lens
Macula_rc
MedullaOblongata
Midbrain
Optic_nerve
Optic_tract
Orbitofrontal
Pituitary
Pons
Retina
Skin
Spinal cord
Thalamus
Ventricles
VSCC

Amygdala
Brain_supratentorial
Brainstem_interior
Brainstem_surface
CaudateNucleus
Cerebellum
Cerebellum_A
Cerebellum_P
Chiasm
Cochlea
Cornea
CorpusCallosum
Fornix
Fovea_rc
Glnd_lacrimal
Glnd_Pineal
Hippocampus
UPDATE
EPTH ATLAS
CONTOURING
2021-02-16
Hippocampus_A
Hippocampus_P
Hypothalamus
Lens
Macula_rc
MedullaOblongata
Midbrain
Optic_nerve
Optic_tract
Orbitofrontal
Pituitary
Pons
Retina
Skin
Spinal cord
Thalamus
Ventricles
VSCC

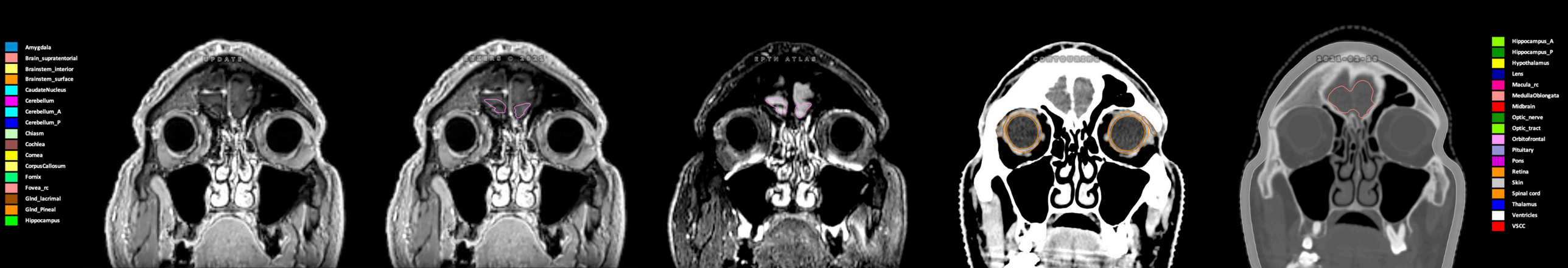
Amygdala
Brain_supratentorial
Brainstem_interior
Brainstem_surface
CaudateNucleus
Cerebellum
Cerebellum_A
Cerebellum_P
Chiasm
Cochlea
Cornea
CorpusCallosum
Fornix
Fovea_rc
Glnd_lacrimal
Glnd_Pineal
Hippocampus
UPDATE
LUKERS © 2021
EPTH ATLAS
CONTOURING
2021-02-18
Hippocampus_A
Hippocampus_P
Hypothalamus
Lens
Macula_rc
MedullaOblongata
Midbrain
Optic_nerve
Optic_tract
Orbitofrontal
Pituitary
Pons
Retina
Skin
Spinal cord
Thalamus
Ventricles
VSCC

Amygdala
Brain_supratentorial
Brainstem_interior
Brainstem_surface
CaudateNucleus
Cerebellum
Cerebellum_A
Cerebellum_P
Chiasm
Cochlea
Cornea
CorpusCallosum
Fornix
Fovea_rc
Glnd_lacrimal
Glnd_Pineal
Hippocampus
UPDATE
FUKUNG © 2023
EPTH ATLAS
CONTOURING
2021-02-28
Hippocampus_A
Hippocampus_P
Hypothalamus
Lens
Macula_rc
MedullaOblongata
Midbrain
Optic_nerve
Optic_tract
Orbitofrontal
Pituitary
Pons
Retina
Skin
Spinal cord
Thalamus
Ventricles
VSCC

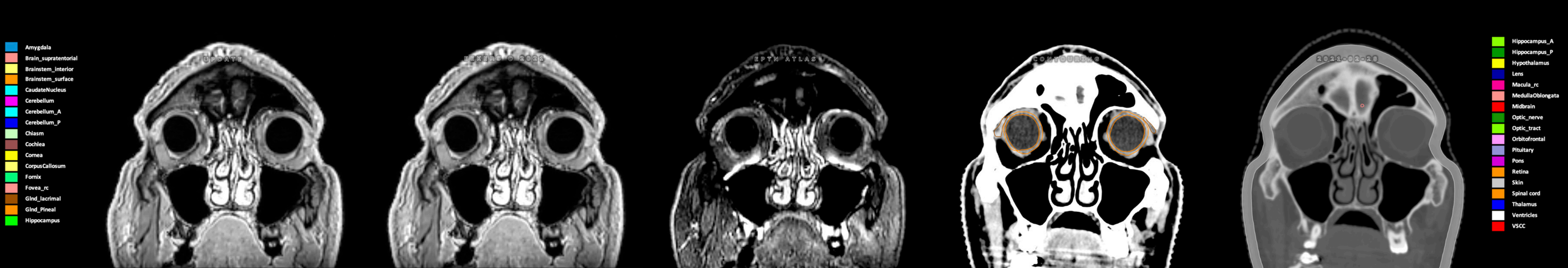
Amygdala
Brain_supratentorial
Brainstem_interior
Brainstem_surface
CaudateNucleus
Cerebellum
Cerebellum_A
Cerebellum_P
Chiasm
Cochlea
Cornea
CorpusCallosum
Fornix
Fovea_rc
Glnd_lacrimal
Glnd_Pineal
Hippocampus
UPDATE
REVIEW 6 2021
EPTN ATLAS
CONTOURING
2021-02-28
Hippocampus_A
Hippocampus_P
Hypothalamus
Lens
Macula_rc
MedullaOblongata
Midbrain
Optic_nerve
Optic_tract
Orbitofrontal
Pituitary
Pons
Retina
Skin
Spinal cord
Thalamus
Ventricles
VSCC

Amygdala
Brain_supratentorial
Brainstem_interior
Brainstem_surface
CaudateNucleus
Cerebellum
Cerebellum_A
Cerebellum_P
Chiasm
Cochlea
Cornea
CorpusCallosum
Fornix
Fovea_rc
Glnd_lacrimal
Glnd_Pineal
Hippocampus
LEKUN'S 2021
EPTN ATLAS
2021-02-28
Hippocampus_A
Hippocampus_P
Hypothalamus
Lens
Macula_rc
MedullaOblongata
Midbrain
Optic_nerve
Optic_tract
Orbitofrontal
Pituitary
Pons
Retina
Skin
Spinal cord
Thalamus
Ventricles
VSCC

Amygdala
Brain_supratentorial
Brainstem_interior
Brainstem_surface
CaudateNucleus
Cerebellum
Cerebellum_A
Cerebellum_P
Chiasm
Cochlea
Cornea
CorpusCallosum
Fornix
Fovea_rc
Glnd_lacrimal
Glnd_Pineal
Hippocampus
ORBITA
EANM'S © 2021
EPTN ATLAS
CONTOURS
2021-02-28
Hippocampus_A
Hippocampus_P
Hypothalamus
Lens
Macula_rc
MedullaOblongata
Midbrain
Optic_nerve
Optic_tract
Orbitofrontal
Pituitary
Pons
Retina
Skin
Spinal cord
Thalamus
Ventricles
VSCC

Amygdala
Brain_supratentorial
Brainstem_interior
Brainstem_surface
CaudateNucleus
Cerebellum
Cerebellum_A
Cerebellum_P
Chiasm
Cochlea
Cornea
CorpusCallosum
Fornix
Fovea_rc
Glnd_lacrimal
Glnd_Pineal
Hippocampus
Hippocampus_A
Hippocampus_P
Hypothalamus
Lens
Macula_rc
MedullaOblongata
Midbrain
Optic_nerve
Optic_tract
Orbitofrontal
Pituitary
Pons
Retina
Skin
Spinal cord
Thalamus
Ventricles
VSCC

Amygdala
Brain_supratentorial
Brainstem_interior
Brainstem_surface
CaudateNucleus
Cerebellum
Cerebellum_A
Cerebellum_P
Chiasm
Cochlea
Cornea
CorpusCallosum
Fornix
Fovea_rc
Glnd_lacrimal
Glnd_Pineal
Hippocampus
UPDATE
EPTN ATLAS
CONTOURING
2021-02-25
Hippocampus_A
Hippocampus_P
Hypothalamus
Lens
Macula_rc
MedullaOblongata
Midbrain
Optic_nerve
Optic_tract
Orbitofrontal
Pituitary
Pons
Retina
Skin
Spinal cord
Thalamus
Ventricles
VSCC

🟦 Amygdala
🟥 Brain_supratentorial
🟨 Brainstem_interior
🟧 Brainstem_surface
🟦 CaudateNucleus
🟪 Cerebellum
🟦 Cerebellum_A
🟦 Cerebellum_P
🟩 Chiasm
🟫 Cochlea
🟨 Cornea
🟨 CorpusCallosum
🟩 Fornix
🟥 Fovea_rc
🟫 Glnd_lacrimal
🟧 Glnd_Pineal
🟩 Hippocampus

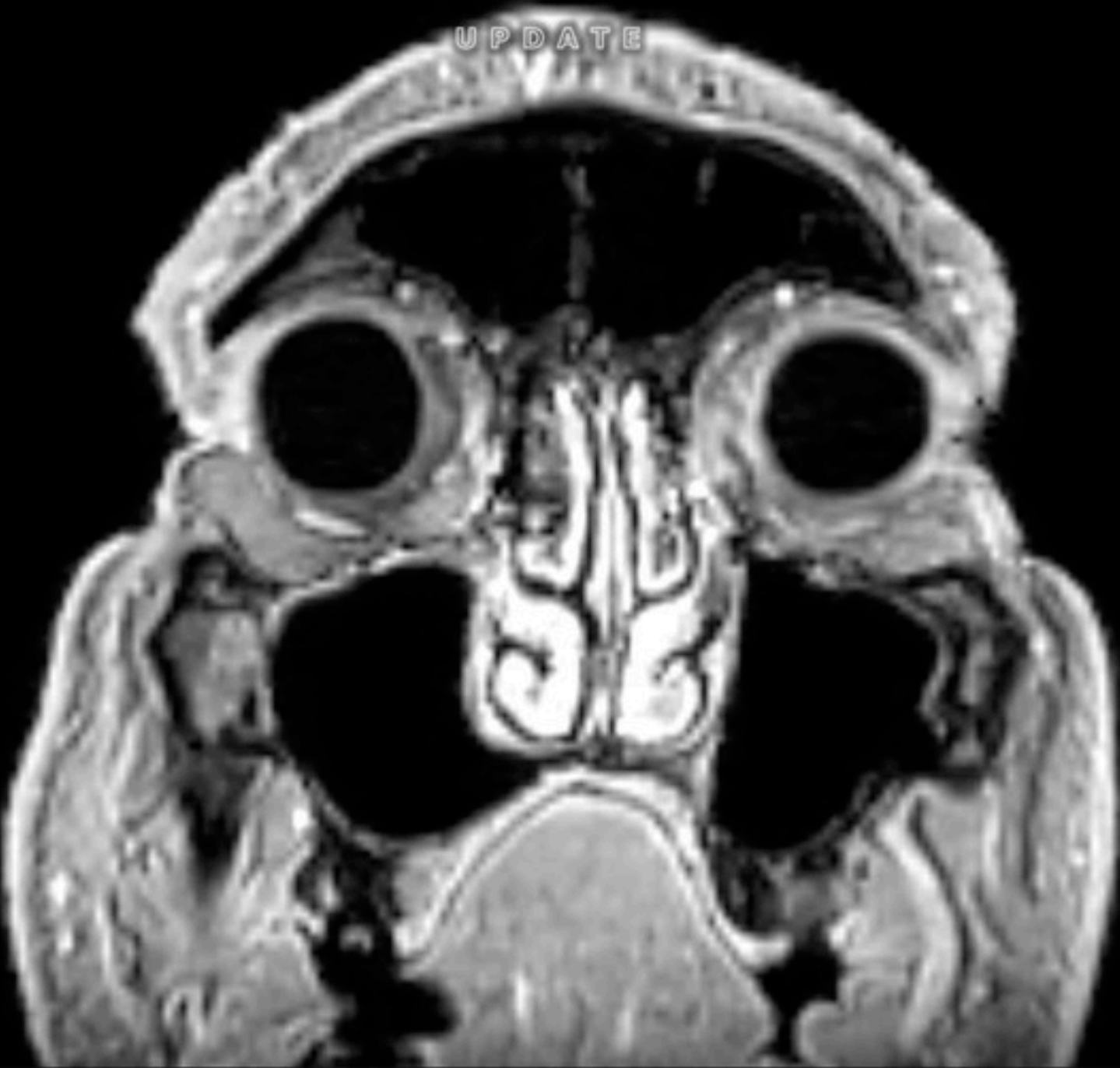

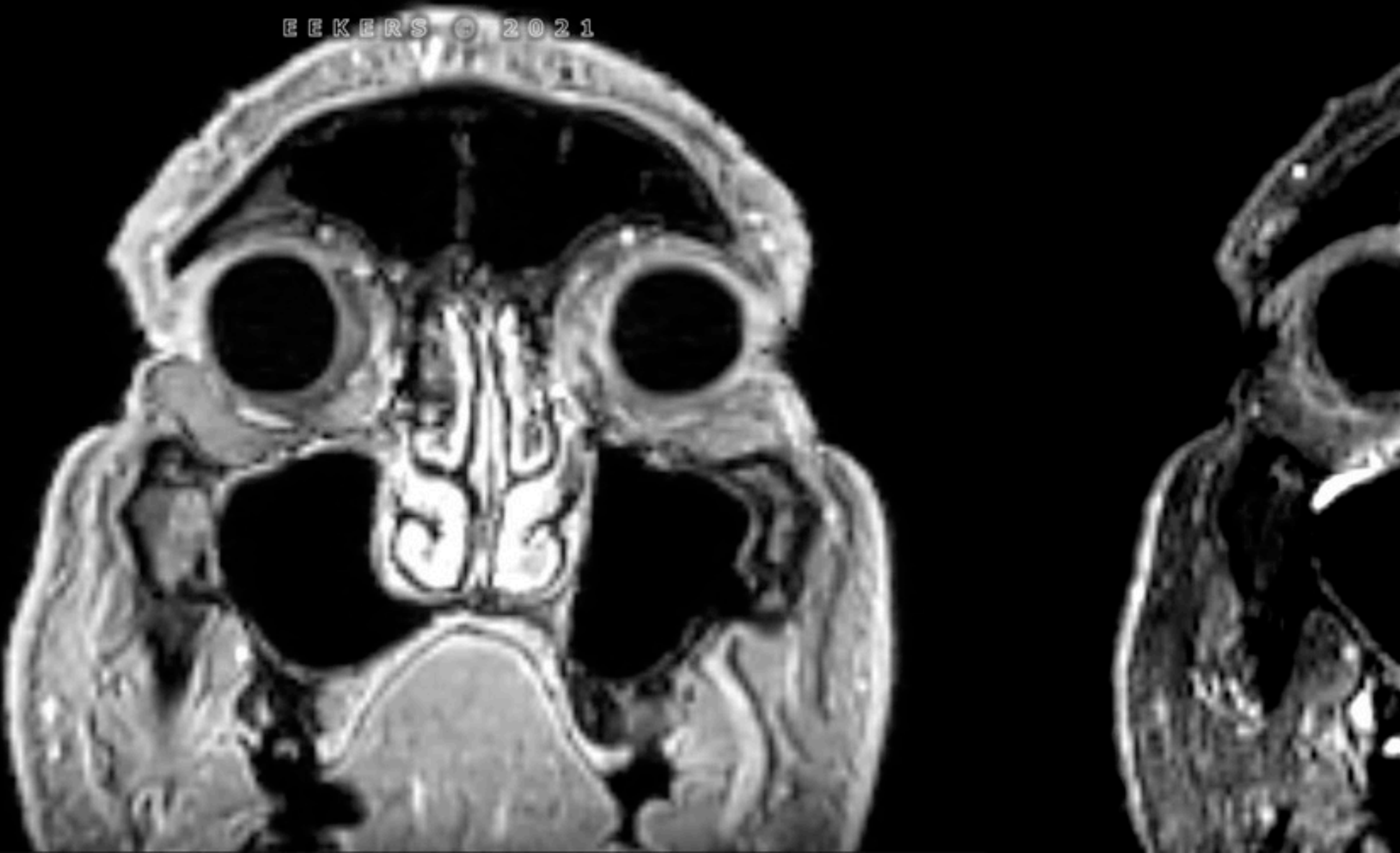

EEKERS © 2021

CONTOURING

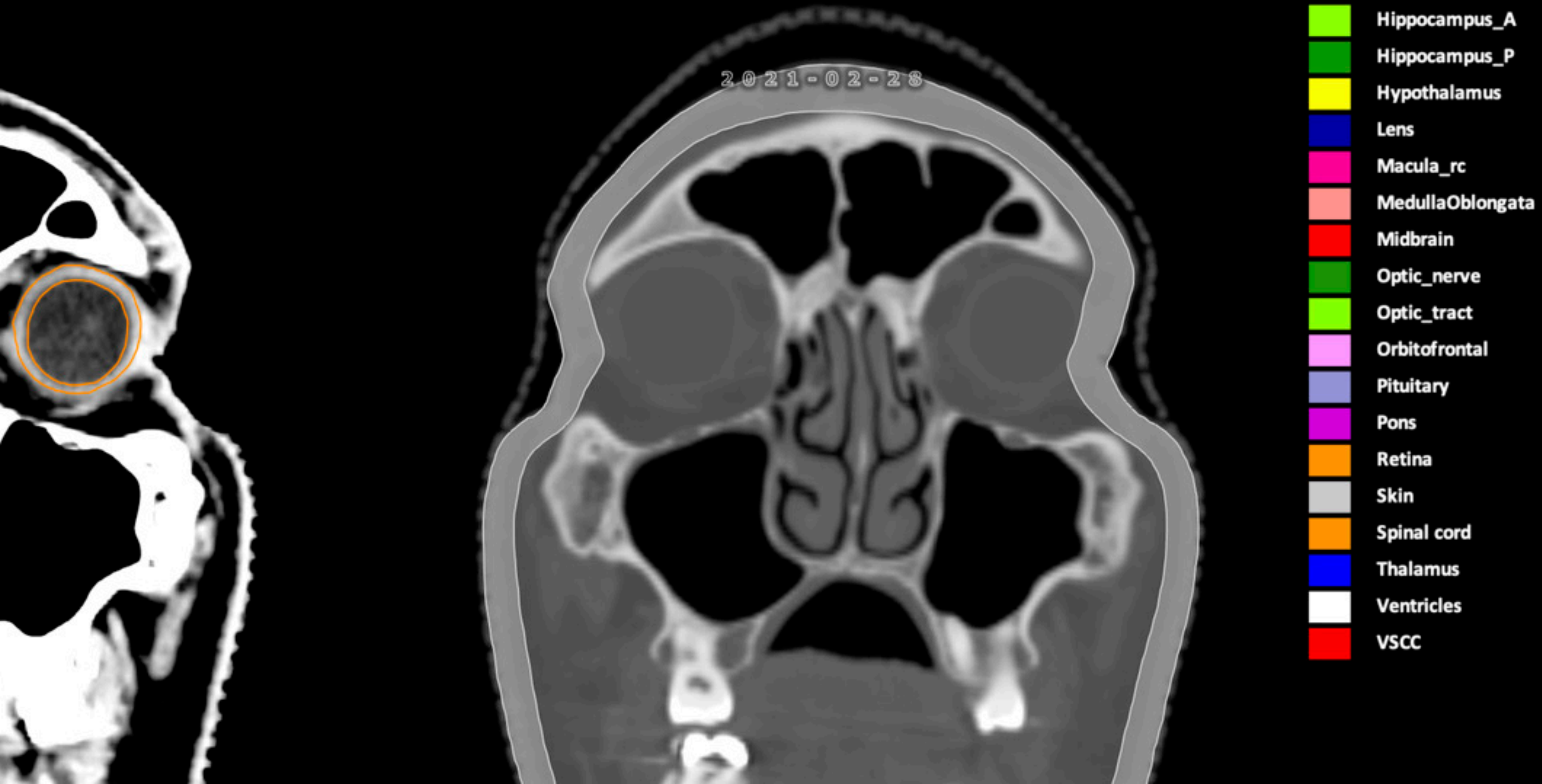
2021-02-28
Hippocampus_A
Hippocampus_P
Hypothalamus
Lens
Macula_rc
MedullaOblongata
Midbrain
Optic_nerve
Optic_tract
Orbitofrontal
Pituitary
Pons
Retina
Skin
Spinal cord
Thalamus
Ventricles
VSCC

Amygdala
Brain_supratentorial
Brainstem_interior
Brainstem_surface
CaudateNucleus
Cerebellum
Cerebellum_A
Cerebellum_P
Chiasm
Cochlea
Cornea
CorpusCallosum
Fornix
Fovea_rc
Glnd_lacrimal
Glnd_Pineal
Hippocampus
Hippocampus_A
Hippocampus_P
Hypothalamus
Lens
Macula_rc
MedullaOblongata
Midbrain
Optic_nerve
Optic_tract
Orbitofrontal
Pituitary
Pons
Retina
Skin
Spinal cord
Thalamus
Ventricles
VSCC

Amygdala
Brain_supratentorial
Brainstem_interior
Brainstem_surface
CaudateNucleus
Cerebellum
Cerebellum_A
Cerebellum_P
Chiasm
Cochlea
Cornea
CorpusCallosum
Fornix
Fovea_rc
Glnd_lacrimal
Glnd_Pineal
Hippocampus
UPDATE
EEKERS © 2021
EPTH ATLAS
CONTOURING
2021-02-18
Hippocampus_A
Hippocampus_P
Hypothalamus
Lens
Macula_rc
MedullaOblongata
Midbrain
Optic_nerve
Optic_tract
Orbitofrontal
Pituitary
Pons
Retina
Skin
Spinal cord
Thalamus
Ventricles
VSCC

Amygdala
Brain_supratentorial
Brainstem_interior
Brainstem_surface
CaudateNucleus
Cerebellum
Cerebellum_A
Cerebellum_P
Chiasm
Cochlea
Cornea
CorpusCallosum
Fornix
Fovea_rc
Glnd_lacrimal
Glnd_Pineal
Hippocampus
UPDATE
EEKERS © 2021
EPTH ATLAS
CONTOURING
2021-02-28
Hippocampus_A
Hippocampus_P
Hypothalamus
Lens
Macula_rc
MedullaOblongata
Midbrain
Optic_nerve
Optic_tract
Orbitofrontal
Pituitary
Pons
Retina
Skin
Spinal cord
Thalamus
Ventricles
VSCC

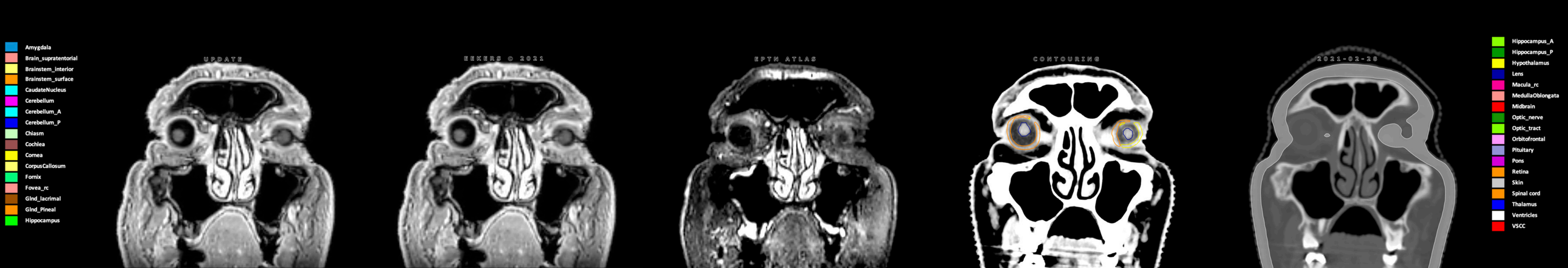
Amygdala
Brain_supratentorial
Brainstem_interior
Brainstem_surface
CaudateNucleus
Cerebellum
Cerebellum_A
Cerebellum_P
Chiasm
Cochlea
Cornea
CorpusCallosum
Fornix
Fovea_rc
Gland_lacrimal
Gland_Pineal
Hippocampus
UPDATE
EEKERS © 2021
EPTH ATLAS
CONTOURING
2021-02-28
Hippocampus_A
Hippocampus_P
Hypothalamus
Lens
Macula_rc
MedullaOblongata
Midbrain
Optic_nerve
Optic_tract
Orbitofrontal
Pituitary
Pons
Retina
Skin
Spinal cord
Thalamus
Ventricles
VSCC

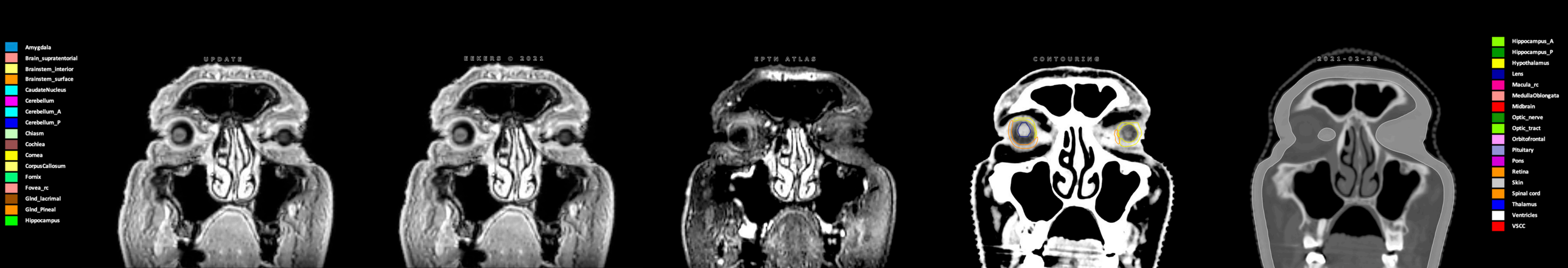
Amygdala
Brain_supratentorial
Brainstem_interior
Brainstem_surface
CaudateNucleus
Cerebellum
Cerebellum_A
Cerebellum_P
Chiasm
Cochlea
Cornea
CorpusCallosum
Fornix
Fovea_rc
Glnd_lacrimal
Glnd_Pineal
Hippocampus
UPDATE
EEKERS © 2021
EPTH ATLAS
CONTOURING
2021-02-28
Hippocampus_A
Hippocampus_P
Hypothalamus
Lens
Macula_rc
MedullaOblongata
Midbrain
Optic_nerve
Optic_tract
Orbitofrontal
Pituitary
Pons
Retina
Skin
Spinal cord
Thalamus
Ventricles
VSCC

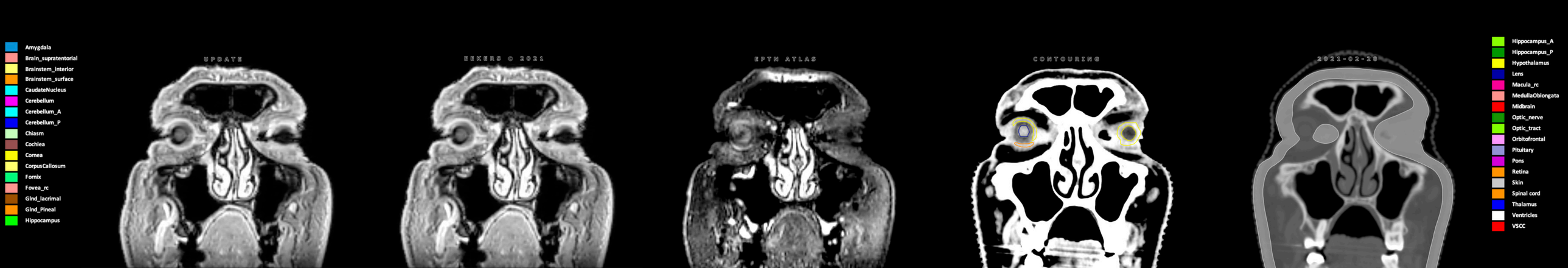
Amygdala
Brain_supratentorial
Brainstem_interior
Brainstem_surface
CaudateNucleus
Cerebellum
Cerebellum_A
Cerebellum_P
Chiasm
Cochlea
Cornea
CorpusCallosum
Fornix
Fovea_rc
Glnd_lacrimal
Glnd_Pineal
Hippocampus
UPDATE
EEKERS © 2021
EPTH ATLAS
CONTOURING
2021-02-28
Hippocampus_A
Hippocampus_P
Hypothalamus
Lens
Macula_rc
MedullaOblongata
Midbrain
Optic_nerve
Optic_tract
Orbitofrontal
Pituitary
Pons
Retina
Skin
Spinal cord
Thalamus
Ventricles
VSCC

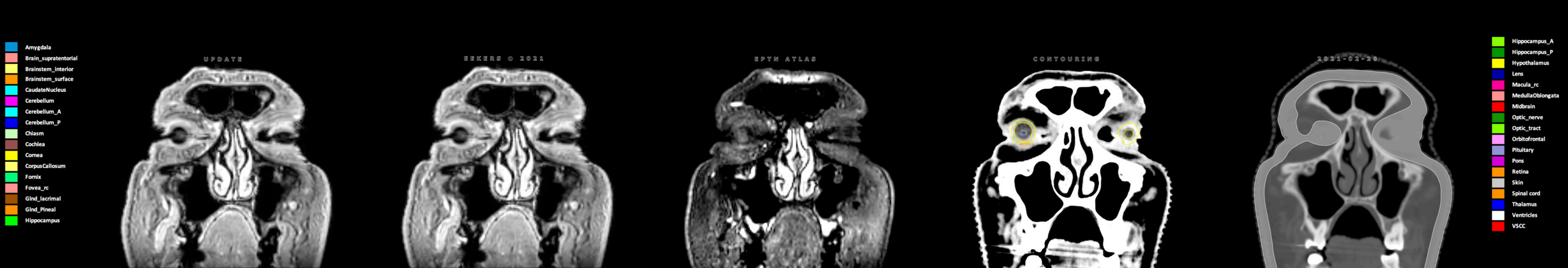
Amygdala
Brain_supratentorial
Brainstem_interior
Brainstem_surface
CaudateNucleus
Cerebellum
Cerebellum_A
Cerebellum_P
Chiasm
Cochlea
Cornea
CorpusCallosum
Fornix
Fovea_rc
Glnd_lacrimal
Glnd_Pineal
Hippocampus
UPDATE
EEKERS © 2021
EPTH ATLAS
CONTOURING
2021-02-28
Hippocampus_A
Hippocampus_P
Hypothalamus
Lens
Macula_rc
MedullaOblongata
Midbrain
Optic_nerve
Optic_tract
Orbitofrontal
Pituitary
Pons
Retina
Skin
Spinal cord
Thalamus
Ventricles
VSCC

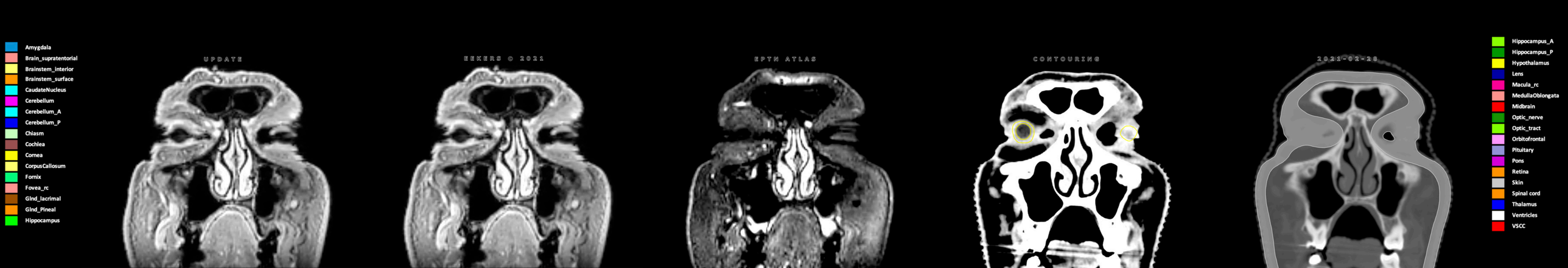
Amygdala
Brain_supratentorial
Brainstem_interior
Brainstem_surface
CaudateNucleus
Cerebellum
Cerebellum_A
Cerebellum_P
Chiasm
Cochlea
Cornea
CorpusCallosum
Fornix
Fovea_rc
Glnd_lacrimal
Glnd_Pineal
Hippocampus
UPDATE
EEKERS © 2021
EPTH ATLAS
CONTOURING
2021-02-28
Hippocampus_A
Hippocampus_P
Hypothalamus
Lens
Macula_rc
MedullaOblongata
Midbrain
Optic_nerve
Optic_tract
Orbitofrontal
Pituitary
Pons
Retina
Skin
Spinal cord
Thalamus
Ventricles
VSCC

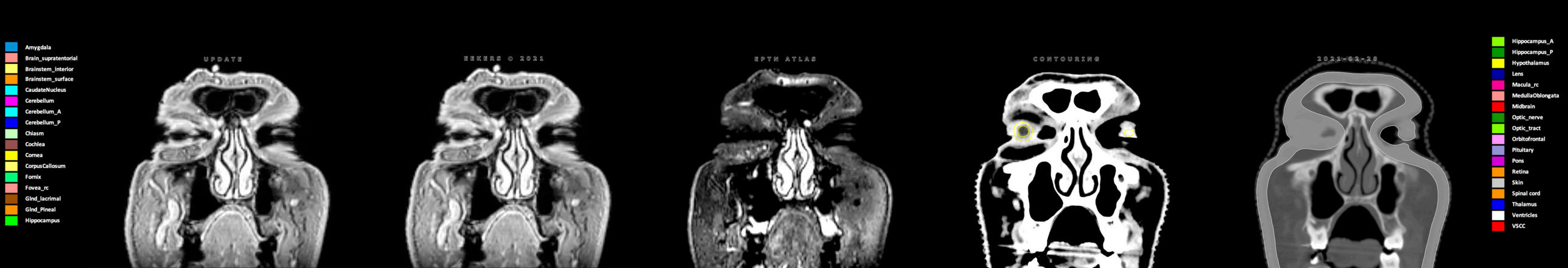
Amygdala
Brain_supratentorial
Brainstem_interior
Brainstem_surface
CaudateNucleus
Cerebellum
Cerebellum_A
Cerebellum_P
Chiasm
Cochlea
Cornea
CorpusCallosum
Fornix
Fovea_rc
Glnd_lacrimal
Glnd_Pineal
Hippocampus
UPDATE
EEKERS © 2021
EPTH ATLAS
CONTOURING
2021-02-28
Hippocampus_A
Hippocampus_P
Hypothalamus
Lens
Macula_rc
MedullaOblongata
Midbrain
Optic_nerve
Optic_tract
Orbitofrontal
Pituitary
Pons
Retina
Skin
Spinal cord
Thalamus
Ventricles
VSCC

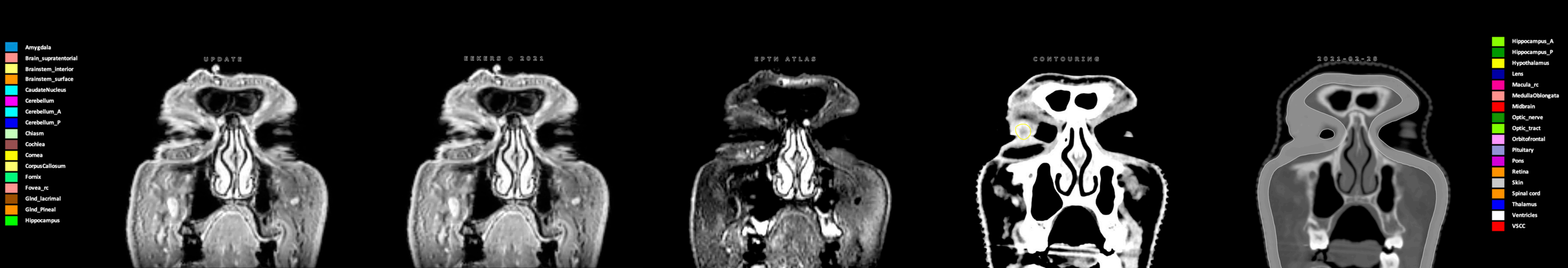
Amygdala
Brain_supratentorial
Brainstem_interior
Brainstem_surface
CaudateNucleus
Cerebellum
Cerebellum_A
Cerebellum_P
Chiasm
Cochlea
Cornea
CorpusCallosum
Fornix
Fovea_rc
Glnd_lacrimal
Glnd_Pineal
Hippocampus
UPDATE
EEKERS © 2021
EPTH ATLAS
CONTOURING
2021-02-28
Hippocampus_A
Hippocampus_P
Hypothalamus
Lens
Macula_rc
MedullaOblongata
Midbrain
Optic_nerve
Optic_tract
Orbitofrontal
Pituitary
Pons
Retina
Skin
Spinal cord
Thalamus
Ventricles
VSCC

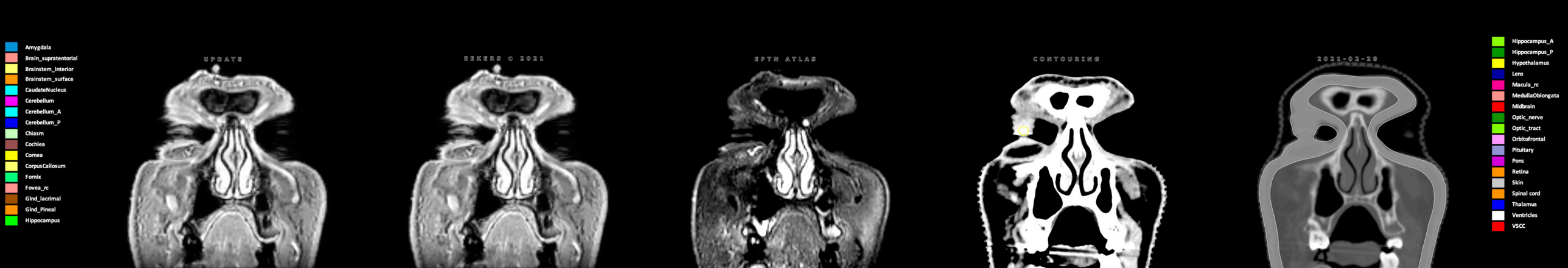
Amygdala
Brain_supratentorial
Brainstem_interior
Brainstem_surface
CaudateNucleus
Cerebellum
Cerebellum_A
Cerebellum_P
Chiasm
Cochlea
Cornea
CorpusCallosum
Fornix
Fovea_rc
Glnd_lacrimal
Glnd_Pineal
Hippocampus
UPDATE
EEKERS © 2021
EPTH ATLAS
CONTOURING
2021-02-28
Hippocampus_A
Hippocampus_P
Hypothalamus
Lens
Macula_rc
MedullaOblongata
Midbrain
Optic_nerve
Optic_tract
Orbitofrontal
Pituitary
Pons
Retina
Skin
Spinal cord
Thalamus
Ventricles
VSCC

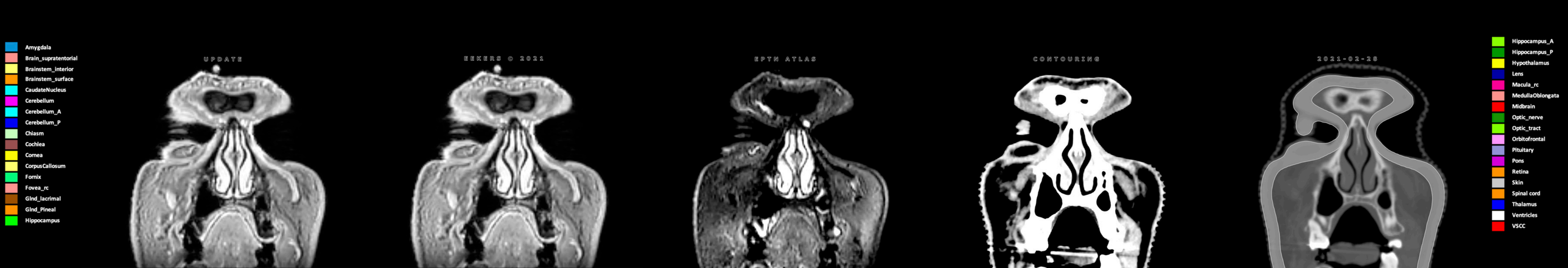
Amygdala
Brain_supratentorial
Brainstem_interior
Brainstem_surface
CaudateNucleus
Cerebellum
Cerebellum_A
Cerebellum_P
Chiasm
Cochlea
Cornea
CorpusCallosum
Fornix
Fovea_rc
Glnd_lacrimal
Glnd_Pineal
Hippocampus
UPDATE
EEKERS © 2021
EPTH ATLAS
CONTOURING
2021-02-28
Hippocampus_A
Hippocampus_P
Hypothalamus
Lens
Macula_rc
MedullaOblongata
Midbrain
Optic_nerve
Optic_tract
Orbitofrontal
Pituitary
Pons
Retina
Skin
Spinal cord
Thalamus
Ventricles
VSCC

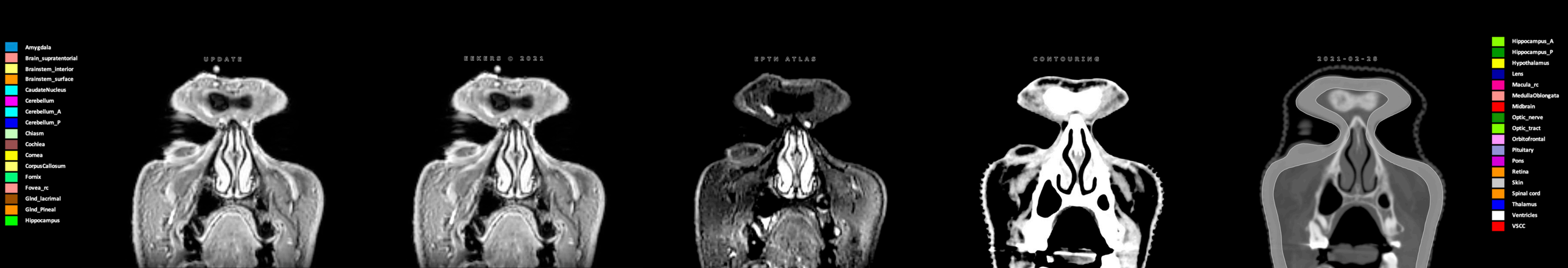
Amygdala
Brain_supratentorial
Brainstem_interior
Brainstem_surface
CaudateNucleus
Cerebellum
Cerebellum_A
Cerebellum_P
Chiasm
Cochlea
Cornea
CorpusCallosum
Fornix
Fovea_rc
Glnd_lacrimal
Glnd_Pineal
Hippocampus
UPDATE
EEKERS © 2021
EPTH ATLAS
CONTOURING
2021-02-28
Hippocampus_A
Hippocampus_P
Hypothalamus
Lens
Macula_rc
MedullaOblongata
Midbrain
Optic_nerve
Optic_tract
Orbitofrontal
Pituitary
Pons
Retina
Skin
Spinal cord
Thalamus
Ventricles
VSCC

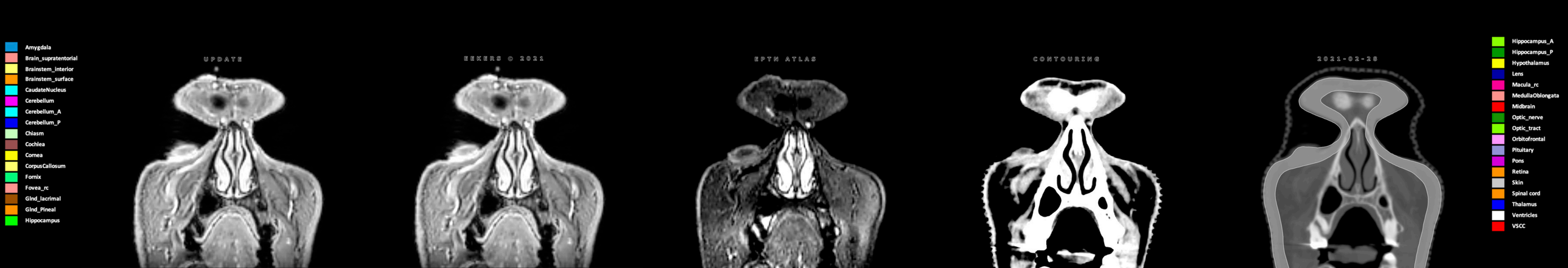
Amygdala
Brain_supratentorial
Brainstem_interior
Brainstem_surface
CaudateNucleus
Cerebellum
Cerebellum_A
Cerebellum_P
Chiasm
Cochlea
Cornea
CorpusCallosum
Fornix
Fovea_rc
Glnd_lacrimal
Glnd_Pineal
Hippocampus
UPDATE
EEKERS © 2021
EPTH ATLAS
CONTOURING
2021-02-28
Hippocampus_A
Hippocampus_P
Hypothalamus
Lens
Macula_rc
MedullaOblongata
Midbrain
Optic_nerve
Optic_tract
Orbitofrontal
Pituitary
Pons
Retina
Skin
Spinal cord
Thalamus
Ventricles
VSCC

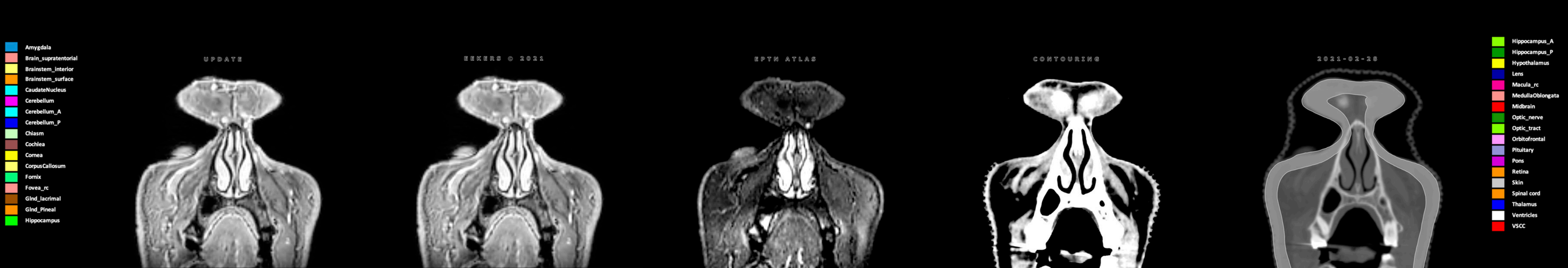
Amygdala
Brain_supratentorial
Brainstem_interior
Brainstem_surface
CaudateNucleus
Cerebellum
Cerebellum_A
Cerebellum_P
Chiasm
Cochlea
Cornea
CorpusCallosum
Fornix
Fovea_rc
Glnd_lacrimal
Glnd_Pineal
Hippocampus
UPDATE
EEKERS © 2021
EPTH ATLAS
CONTOURING
2021-02-28
Hippocampus_A
Hippocampus_P
Hypothalamus
Lens
Macula_rc
MedullaOblongata
Midbrain
Optic_nerve
Optic_tract
Orbitofrontal
Pituitary
Pons
Retina
Skin
Spinal cord
Thalamus
Ventricles
VSCC

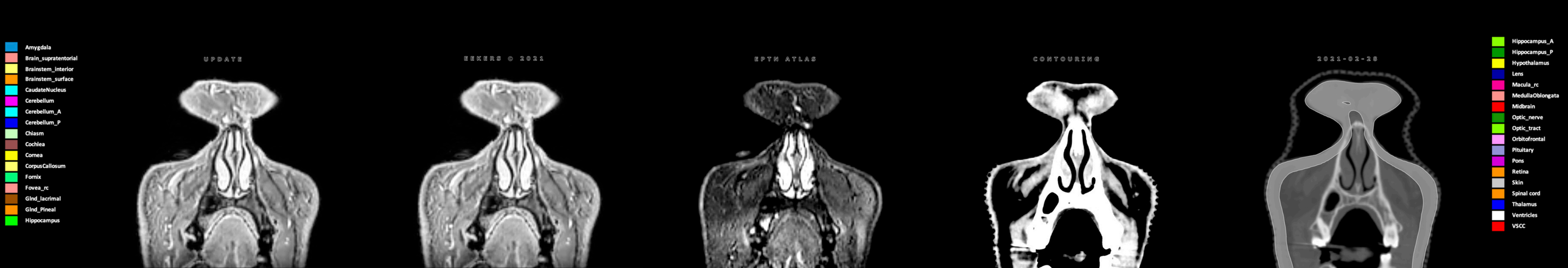
Amygdala
Brain_supratentorial
Brainstem_interior
Brainstem_surface
CaudateNucleus
Cerebellum
Cerebellum_A
Cerebellum_P
Chiasm
Cochlea
Cornea
CorpusCallosum
Fornix
Fovea_rc
Glnd_lacrimal
Glnd_Pineal
Hippocampus
UPDATE
EEKERS © 2021
EPTH ATLAS
CONTOURING
2021-02-28
Hippocampus_A
Hippocampus_P
Hypothalamus
Lens
Macula_rc
MedullaOblongata
Midbrain
Optic_nerve
Optic_tract
Orbitofrontal
Pituitary
Pons
Retina
Skin
Spinal cord
Thalamus
Ventricles
VSCC